

POTENTIAL AMELORATIVE EFFECT OF *PANAX GINSENG* ON HEPATORENAL DAMAGE OCCURRED IN HYDROXYUREA-TREATED RATS

Samar S. Elblehi*, Dina R. S. Gad El-Karim

Department of Pathology and Clinical Pathology, Faculty of Veterinary Medicine, Alexandria University, 11511, Egypt

*Corresponding author, E-mail: samarsaad30@yahoo.com

Abstract: Hydroxyurea (HU) is an anti-neoplastic drug which is used for treatment of many types of tumors; however, its wide range of deleterious effects may limit its medical usage. This study was conducted to assess the possible protective role of *Panax ginseng* extract (Ginseng) against HU- induced hepato-renal damage in rats. Forty male Wistar albino rats were randomly divided into four equal groups (10 rats each). Group I (control) received 1ml purified water. Group II (Ginseng-treated) received 200 mg/kg body weight (b.wt) of *Panax ginseng* extract. Group III (HU-treated) received HU at a dose of 500 mg/kg b.wt. Group IV (HU plus ginseng) received HU and *Panax ginseng* extract in similar doses of group II and III. All the treatments were administered orally. Treatment with *Panax ginseng* failed to ameliorate the hematological alterations caused by HU, but, its ability to alleviate hepato-renal cytotoxic effect was proved through significant reduction in plasma level of hepato-renal injury biomarkers (AST, ALT, GGT, urea and creatinine) which were elevated in HU-treated group. Also, this effect was affirmed by decreased level of plasma pro-inflammatory cytokines (TNF- α and IL-6) and enhanced anti-oxidant state (decreased MDA content and increased GPX activity) of hepato-renal tissues upon *Panax ginseng* extract administration with HU. Histopathologically, HU induced impairments in both hepatic and renal tissues of the treated rats. Conversely, concurrent administration of ginseng with HU partially improved these alterations.

Key words: hydroxyurea; hepato-renal toxicity; *Panax ginseng*; rats

Introduction

Hydroxyurea (HU) as an anti-neoplastic drug is used in humans and dogs for the treatment of chronic myelogenous leukemia, polycythemia, ovarian cancer, melanoma, and squamous cell carcinoma of the head and neck. Also, it has been used for treatment of renal cell carcinoma, transitional carcinoma of the urinary bladder, prostatic carcinoma, and carci-

noma of the uterine cervix in addition to thrombocytosis (1). Moreover, HU has been used for treatment of mast cell tumor and hypereosinophilic syndrome in dogs (2,3). It is the only approved option to be used in humans with sickle-cell disease as it reduces vaso-occlusive crises frequency, blood transfusions, the number of days spent in hospital and mortality of these patients (4). That's because administration of HU to sickle-cell disease patients increases the production of erythrocytes fetal hemoglobin which

can carry more oxygen than adult hemoglobin (5), decreases circulating neutrophils, enhances the deformability of erythrocytes, decrease adhesion of erythrocytes to endothelium, promotes vasodilation through production of nitric oxide and increasing adenosine deaminase activity in circulating monocytes leading to lower adenosine levels (6, 7). The mechanism of action of HU as an anti-neoplastic drug depends on its ability to arrest rapidly dividing cells at S phase of cell division (8) through inhibition of the class I ribonucleotidoreductase enzyme (9) which is responsible for the formation of deoxyribonucleotides from ribonucleotides (10) by inactivating the tyrosyl radical required for enzyme activity leading to massive reduction in the production of deoxyribonucleotides that are necessary for DNA replication (11,12).

HU is generally tolerated however it has a low safety margin due to myelosuppression, as the earliest and most common reported adverse findings in human patients were pan-leukopenia, anemia and thrombocytopenia (3, 5, 13). Additionally, growth retardation spermatogenic arrest, hematopoietic, lymphoid, cardiovascular, and gastrointestinal toxicity associated with hemosiderosis of spleen and liver have been observed in dog toxicity studies (13, 14). In rats administration of HU at high doses induced reduction in the body weight gain, anemia, leukocytopenia, thrombocytopenia associated with hypocellularity of lymphoid organs and bone marrow; epithelial degeneration and/or dysplasia of the stomach and small intestine (14) and decreased fertility in males as it induced testicular atrophy and decreased sperm production (15), also, it can induce hepatic damage with fatty changes (13). Cardiovascular effects and slight methemoglobinemia were detected in some species "at doses higher than clinical levels" (13, 16), skin and nail lesions have been reported in human and canine patients (2,17,18). In addition, HU can induce lung toxicity with pulmonary edema, lung infiltration and dyspnea (19), and pulmonary fibrosis in a minority of patients (20).

Traditional herbal medicine has become the point of attraction in the clinical and experi-

mental research. *Panax ginseng* (Korean ginseng), commonly known as ginseng is a famous medicinal plant that has been used extensively in traditional Chinese medicine for more than 2,000 years (21-24). Bioactive constituents of ginseng include ginsenosides, polysaccharides, phenolics, flavonoids, and polyacetylenes (25). In particular, the main active components of ginseng are the ginsenosides (or triterpenoid-saponins), as well as about 38 more types of ginsenosides have been identified approximately (26). These compounds are proved to be responsible for most of the favorable effects of ginseng, which has a wide range of protective or therapeutic effects against many diseases. Ginsenosides have been studied intensively as the main active components of ginseng that have a variety of pharmacological effects, including anti-diabetes (27), anti-oxidant and anti-inflammatory (28), anti-aging (29), anti-obesity (30), immune modulator and anti-tumor effect (31, 32). To the best of our knowledge, very few detailed reports of HU induced toxicity in lab animals have been published and the published reports were insufficient to demonstrate the hepato-renal effect of HU administration. In this context, this study was conducted to assess the adverse effects of HU administration to male albino rats up to 1 month and the ability of *Panax ginseng* to ameliorate these effects.

Materials and methods

Chemicals

Commercially available formulation of hydroxyurea capsules (Hydrea®500mg, E R Squibb & Sons Ltd., England) was used. *Panax ginseng* extract were obtained in form of capsules containing 550 mg of Korean red ginseng extract, 8% ginsenosides (Nature's Way, USA).

Animals and experimental design:

Forty male Wistar albino rats, 6–8 weeks old and 180–200 g body weight were obtained from the closed bred colony in Faculty of Agriculture, Alexandria University, Egypt. Rats were housed in metal cages under controlled environmental conditions (24–27 °C temperature, 55% RH, and 12 h light/dark cycle) for 2 weeks.

They were observed carefully during this period to make sure that they were free from any apparent health problem. All animals fed on a standard laboratory diet and received water *ad libitum* during the experiment. This study was approved by committee of Care and Use of Laboratory Animals of Alexandria University.

After the acclimatization period, rats were allocated into four groups (10/each). All groups received daily oral intubation using stomach tube and the treatment lasted for 30 days as the following: Group I (control) received 1ml purified water (the vehicle used for HU). Group II (ginseng-treated) received 200 mg/kg b.wt of *Panax ginseng* extract (33). Group III (HU-treated) received hydroxyurea at a dose of 500 mg/kg b.wt (34), HU solution was freshly prepared by tablets dissolving in purified water. Group IV (HU + ginseng) received hydroxyurea and ginseng extract in similar doses of group II and III. Twenty four hours after the last dose, the rats of each group were euthanized after light ether anesthesia to be subjected to the following studies.

Hematological studies

Anti-coagulated blood samples (in EDTA containing tubes) were collected from retro-orbital venous plexus for determination of erythrocytic (RBCs) count, and platelets count in addition to total and differential leukocytic count (Exigo® veterinary hematology system, Sweden) and for separation of plasma by samples centrifugation at 1000×g for 10 min.

Biochemical analysis

Plasma activities of AST, ALT and GGT, in addition to levels of urea and creatinine were determined using commercially available kits. Plasma level of IL-6 and TNF-alpha were detected by quantitative sandwich enzyme immunoassay method using Rat specific ELISA kits (abcam, USA).

Antioxidant studies

About 1 g of kidney and liver of each euthanized animal were separated, perfuse with phosphate buffer saline solution (PBS) solution (pH, 7.4) containing 0.16 mg/ml heparin to remove any blood or clots, and homogenized in 9

ml PBS solution using tissue homogenizer (Glas-Col. Tissues homogenizer, China). Homogenate aliquots were centrifuged at 10,000 × g for 30 min, supernatant were removed and stored at -80 till the time of assessment of concentration of malondialdehyde (MDA) and activity of glutathione peroxidase enzymes (GPX) using locally available kits (Biodiagnostic-Egypt; Biovision, USA) and as previously described (35). Protein content was detected using Bradford's reagent (Sigma-Aldrich, USA).

Histopathological examination

Following necropsy specimens of livers and kidneys of each rat were collected and rapidly fixed for at least 24h in 10% neutral buffered formalin. The fixed specimens were processed through the conventional paraffin embedding technique, sectioned at 5 microns and stained with Mayer's haematoxylin and eosin (H&E). Stained sections were examined by light microscope and photographed using digital camera.

Semiquantitative histopathological scoring system

Semi quantitative histological scoring was carried out for the liver and kidneys slides. Five fields (×100) were randomly selected from each rat in each group, and the most important pathological alterations were selected and scored in each organ; the severity of lesion was estimated according to the percentage of affected area/entire section where in: 0 = absence of lesion, 1 = 5–25%, 2 = 26–50%, and 3 = ≥50%

Statistical analysis

The statistical analysis was carried-out using one way analysis of variance (ANOVA) for studying of the effect of different treatment groups on different parameters studied using SAS, (2004) (36).

Results

Hematological results

As presented in Table 1, blood picture of HU-treated rats significantly showed a decrement in RBCs count which coupled by significant decrease in total leukocytic count (TLC), granulocytes, lymphocytes and monocytes

counts in addition to platelets count when compared to control group. Unfortunately, co-administration of ginseng with HU failed to increase the diminished values of the previously listed parameters of blood picture as compared to HU-treated rats. The sole treatment with ginseng did not enhance any of these hematological parameters compared to control group.

Biochemical changes

As shown in Table 2, treatment of rats with HU evoked significant elevation in plasma activity of AST, ALT and GGT enzymes when compared to control group. Administration of ginseng with HDU significantly decreases plasma activity of these enzymes if compared to HU-treated animals. In the same manner, treatment with HU led to significant increase in plasma concentration of urea and creatinine which accompanied by significant decrease in plasma albumin concentration compared to control group. Comparatively with HU-treated group, co-administration of ginseng with HU significantly ameliorated the changes in these parameters. While, treatment with ginseng alone significantly decreased plasma activity of AST and ALT without any significant effect on the previously elucidated plasma hepato-renal function biomarkers compared to control group.

Plasma level of inflammatory cytokines

Plasma level of TNF-alpha and IL6 revealed a significant increase in HU-treated rats in comparison with control group. Meanwhile, their values were significantly diminished following co-administration of ginseng as compared to HU-treated animals. Moreover, administration of ginseng alone did not produce any alteration in plasma level of previously detected pro-inflammatory cytokines as compared to control group. (Table 2).

Oxidative changes

The level of MDA recorded a significant increase in hepatic and renal tissues of HU-treated rats which was accompanied by significant decline in GPX activity in these tissues when compared to control group. These elevations were significantly ameliorated toward

normal control level upon co-treatment with ginseng. Treatment with ginseng alone did not reveal any significant changes in oxidant/anti-oxidant parameters in relation to control group (Table 3).

Histopathological examination

The histopathological changes detected in livers and kidneys slides were represented in Figs. (1 and 2) and Table (4) which summarized the lesions' incidence and severity reported in HU and HU+ Ginseng-treated groups. No histopathological alterations were detected in either control or Ginseng-treated rats groups.

Liver

Control (Fig.1A) and Ginseng-treated rats' livers showed normal histological structures. Meanwhile, livers of HU -treated rats showed diffuse hepatocytic cytoplasmic vacuolation of both fatty type (sharply outlined vacuoles, Fig.1B, Table4) and hydropic type (hazy border vacuoles). Widening of the hepatic sinusoids, hypertrophy of Kupffer cells, widespread moderate to severe congestion and multifocal areas of hemorrhages (Fig1C) were noticed. Furthermore, multifocal areas of hepatocellular necrosis with mononuclear cells infiltrations were evident (Fig. 1D, Table 4). The Portal triads were thickened with edema and mononuclear cell infiltrations associated with atrophied hepatic cords (Fig1E, Table4). Conversely, livers of HU+ Ginseng- treated rats showed the previous described lesions but they were less in the severity and distribution (Fig.1F, Table4).

Kidney

Control (Fig.2A) and Ginseng-treated rat's kidneys exhibited normal histological limits of the glomeruli and renal parenchyma. HU -treated rats showed degenerated tubular epithelium with star-shaped tubular lumen. Also, epithelium attenuation and necrosis with desquamated necrotic debris and inter tubular hyaline casts (Fig.2B, Table 4) were noticed. Regarding to the glomerular lesions, compressed capillary tufts with increased urinary spaces and presence of necrotic remnants of capillary tufts (Fig. 2C, Table 4) were recorded. Throughout the renal parenchyma, the interstitial tissue exhibited

multifocal areas of interstitial nephritis with mononuclear cells infiltration, inter tubular edema and marked tubular dilatation (Fig. 2D). In addition, vascular congestion, moderate perivascular edema associated with lymphocytic cells infiltration and moderate fibroplasia (Fig.

2E, Table 4) were noticed. In contrast, the detected renal alternations in HU+ Ginseng-treated group were reduced in the severity and distribution with marked improvement of the renal tissue (Fig. 2 F, Table 4) as compared to HU -treated group.

Table 1: Effect of HU and its combination with Ginseng on blood picture of male Wistar albino rats.

Groups	Control	Ginseng	HU	HU+ginseng
RBCs($\times 10^6/\mu\text{L}$)	7.86 \pm 0.27a	7.85 \pm 0.27a	5.40 \pm 0.19b	5.28 \pm 0.24b
TLC($\times 10^3/\mu\text{L}$)	14.12 \pm 0.23a	14.96 \pm 0.28a	8.56 \pm 0.26b	8.31 \pm 0.25b
Granulocyt($\times 10^3/\mu\text{L}$)	4.18 \pm 0.26a	4.59 \pm 0.13a	1.82 \pm 0.05b	1.84 \pm 0.03b
Lymphocyte($\times 10^3/\mu\text{L}$)	8.46 \pm 0.21a	8.76 \pm 0.23a	5.78 \pm 0.27b	5.68 \pm 0.25b
Monocyte($\times 10^3/\mu\text{L}$)	1.47 \pm 0.16a	1.51 \pm 0.15a	0.95 \pm 0.07b	0.93 \pm 0.06b
Platelets($\times 10^3/\mu\text{L}$)	555.20 \pm 8.01a	552.80 \pm 9.32a	330.80 \pm 17.31b	329.00 \pm 17.42b

All values are expressed as mean \pm Std. Error. Means within the same raw of different litters are significantly different at ($P < 0.05$). H: Hydroxyurea, Ginseng: *Panax ginseng* extract

Table 2: Effect of different treatments on different plasma hepatic and renal function biomarkers and plasma pro-inflammatory cytokines in male Wistar albino rats

Groups	Control	Ginseng	HU	HU+ginseng
AST(U/L)	51.40 \pm 2.60b	48.40 \pm 2.93c	84.70 \pm 2.01a	58.30 \pm 4.09b
ALT(U/L)	34.20 \pm 2.99c	32.40 \pm 2.86d	72.60 \pm 5.18a	47.60 \pm 2.96b
GGT(U/L)	31.00 \pm 3.30c	31.20 \pm 2.29c	57.00 \pm 2.57a	39.90 \pm 2.90b
Urea(mg/dl)	54.20 \pm 2.51b	50.60 \pm 1.98c	80.40 \pm 2.94a	53.84 \pm 4.00b
Creatinine(mg/dl)	0.54 \pm 0.01c	0.53 \pm 0.01c	0.76 \pm 0.01a	0.63 \pm 0.01b
Albumin(g/dl)	6.02 \pm 0.06a	5.92 \pm 0.13a	4.09 \pm 0.08c	5.02 \pm 0.18b
TNF(pg/ml)	27.76 \pm 2.17c	28.20 \pm 2.33c	236.10 \pm 17.65a	138.50 \pm 6.67b
IL6 (pg/ml)	18.94 \pm 1.52c	17.50 \pm 1.50c	125.96 \pm 5.65a	64.58 \pm 8.42b

All values are expressed as mean \pm Std. Error. Means within the same raw of different litters are significantly different at ($P < 0.05$).

Table 3: Effect of different treatments on hepatic and renal MDA and GPX in male Wistar albino rats

Groups	Control	Ginseng	HU	HU+ginseng
Liver MDA ($\mu\text{mol/g}$ protein)	8.98 \pm 0.93c	7.59 \pm 0.53c	26.96 \pm 1.44a	26.96 \pm 1.44a
Kidney MDA ($\mu\text{mol/g}$ protein)	5.03 \pm 0.87c	4.31 \pm 0.74c	22.46 \pm 2.06a	13.57 \pm 0.92b
Liver GPX (U/mg. protein)	3.28 \pm 0.29a	3.66 \pm 0.37a	1.81 \pm 0.12b	2.84 \pm 0.28a
Kidney GPX (U/mg protein).	3.04 \pm 0.42ab	3.44 \pm 0.26a	1.74 \pm 0.15c	2.37 \pm 0.19b

All values are expressed as mean \pm Std. Error. Means within the same raw of different litters are significantly different at ($P < 0.05$).

Discussion

Hydroxyurea is a potent anti-neoplastic drug which is widely used to prevent painful crises of sickle cell anemia (37). Most available toxicity data from animals are present only in product labels, which are incomplete, and are often found only in summary statements (reviewed by Liebelt et al. 2007) (38). This study aimed to evaluate the toxic side effects of HU on liver and kidney tissues of rats and the probable role of *Panax ginseng* in refinement of such effects. HU is a small molecule, which is rapidly taken up by water and distributed widely throughout the body; it may reach vulnerable areas rapidly causing prompt cytotoxicity (39,40).

Myelosuppression is one of the major associated complications of the treatment with hydroxyurea (41), as HU can kill S-phase colony-forming unit (CFU) cells of bone marrow and retard the entry of surviving cells into S-phase of division (42) and this may explain the significant reduction in RBCs, leukocytic and platelets count of HU-treated group. Also, HU has the ability to induce damage to erythrocytes membranes due to erythrocytic membrane lipid peroxidation causing lysis of RBC (43) which

can be considered as another illustration for the decrement of RBCs count. On the other hand, hydroxyurea inhibit DNA synthesis in germinal center of lymph follicle (44) which may explain the cause of lymphopenia in HU-treated animals. It was suggested that hydroxyurea can induce production of intracellular ROS (42-47) which are involved in cytotoxic effect of hydroxyurea (48,49), as the mechanisms of action of HU depends on its rapid metabolism which produce carbomoylnitroso intermediate which then turned to nitroxide compounds (including nitric oxide) that are responsible for most of toxic effects of HU (50,51). These nitroxides act as free radicals which enhance formation of reactive oxygen species, creating oxidative stress state, interacting with nucleic acids and proteins to offset cellular functions, and altering cell signaling (51). This could be the reason for the elevated plasma activities of different liver enzymes (AST, ALT and GGT) due hepato cellular necrosis and membrane damage causes the release of these enzymes into the circulation in addition to increased plasma level of urea and creatinine. This Indicated oxidative hepato-nephrotoxic effect of HU which was affirmed by our histopathological findings.

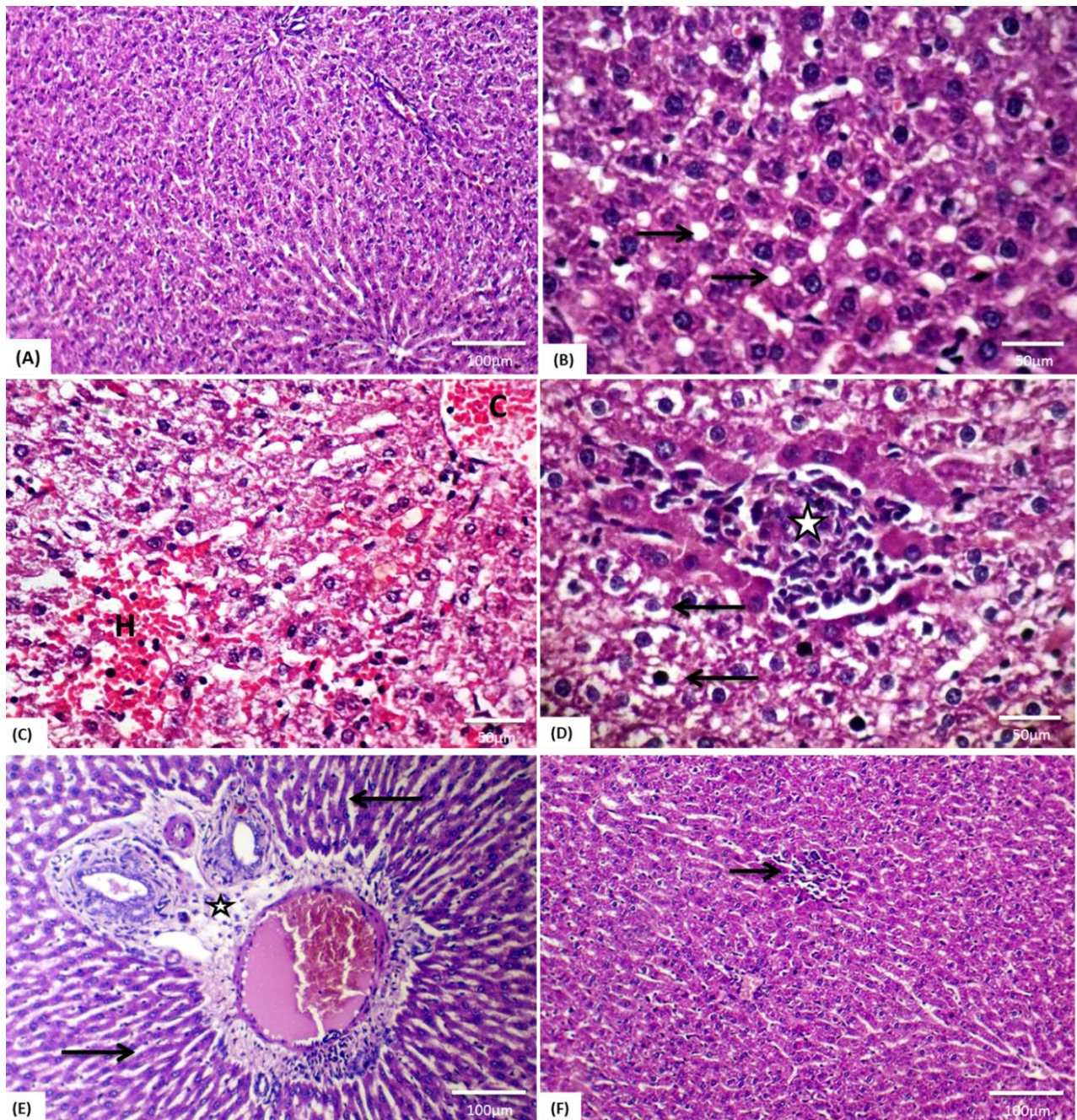


Figure 1: Representative photomicrograph of rat livers stained with HE: (A) Normal histoarchitecture of a control rat liver (X100). (B,C,D&E) livers of **HD**- treated rats: (B) Hepatocytes showing sharply outlined fat vacuoles (arrows, X400), (C) Replacement of the necrotic hepatocytes with RBCs and mononuclear cells (H) associated with congestion (C, X400), (D) Hepatocyte cytoplasm showing hazy border vacuoles (arrows) in and hepatocellular necrosis with mononuclear cells infiltrations (asterisks, X400), (E) Thickening of the portal areas with edema and mononuclear cells infiltrations (asterisks) with newly formed bile ductules and atrophied hepatic cords (arrows, X100). (F) **HD+ Ginseng** -treated rats showed marked improvement of the hepatic tissue with minute area of hepatocellular necrosis (arrow, X100)

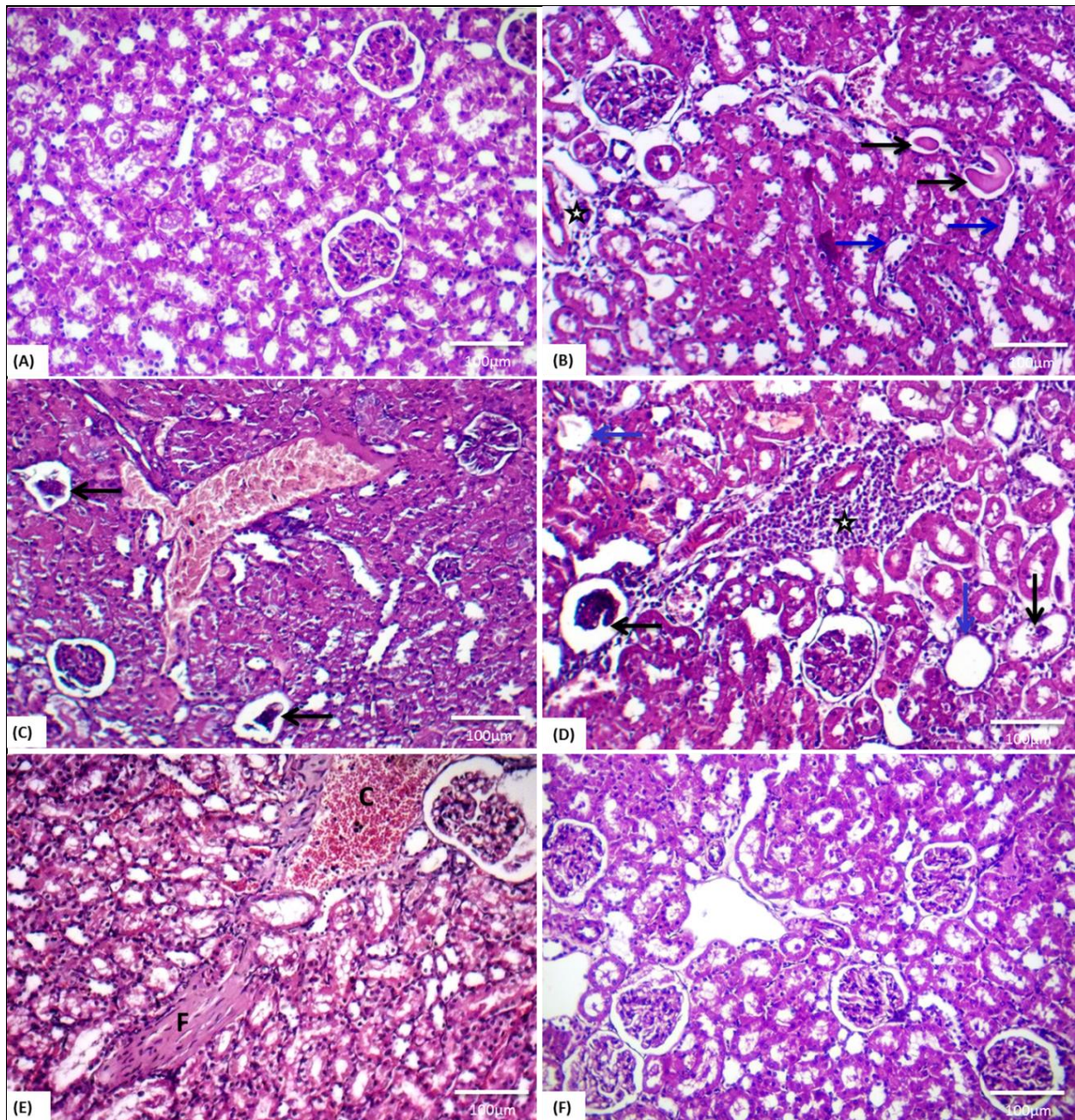


Figure 2: Representative photomicrograph of rat kidneys stained with HE.X100: (A) Normal histoarchitecture of a control rat kidney. (B,C,D&E) kidneys of HU- treated rats: (B) Entertubular hyaline casts (black arrows), thinning and attenuation of the tubular epithelium (blue arrows) and perivascular lymphocytic cells infiltration (asterisk), (C) Necrotic capillary tufts with widening of urinary space (arrows) associated with vascular congestion,(D) Interstitial mononuclear cells infiltrations in the renal cortex (asterisk) with atrophied and necrotic glomerular tufts (black arrows) cystically dilated renal tubules (blue arrows), (E) Vascular congestion(c) and fibroplasia of interstitial tissue (F). (F) HU + Ginseng -treated rats showing marked improvement of the renal tissue.

Table 4: Incidence and Severity of histopathological lesions recorded in livers and kidneys tissues of HU and HU+Ginseng- treated rats

Scored lesions	Incidence ¹ and Severity ² of histopathological Lesions							
	HU-treated rats				HU+ Ginseng-treated rats			
	Ab- sent (-)	Mild (+)	Moder- ate (++)	Severe (+++)	Ab- sent (-)	Mild (+)	Moder- ate (++)	Severe (+++)
Liver								
a -Hepatocytic vac- ular and hydropic degeneration	0	0	4	6	0	0	8	2
b -Hepatocytic fat- tyvaculation	0	0	7	3	0	6	3	1
c -Congestion of cen- tral and portal veins.	0	1	3	6	1	6	4	0
d -Hepatocellular ne- crosis.	0	0	8	2	0	7	2	1
e -Periportal infilama- tory cells infiltra- tions.	0	0	6	4	0	5	3	2
Kidneys								
a -Inter tubular cast formation	0	1	6	3	0	6	3	1
b -Tubular epithelium necrosis	0	0	3	7	0	7	2	1
c -Vascular conges- tion (cortical or me- dullary)	0	0	4	6	0	6	4	0
d -Glomerular lesions	0	0	7	3	0	8	2	0
e -Interstitial mononu- clear cells infiltra- tions	0	0	8	2	0	6	4	0
f -Interstitial fibrosis	0	0	6	4	3	5	2	0

¹Number of rats with lesions per total examined (10 rats).

²Severity of lesions was graded by estimating the percentage area affected in the entire section.

-Lesion scoring: (0) absence of the lesion=0%, (+) mild=5-25%, (++) moderate=26-50% and (+++) severe \geq 50% of the examined tissue sections. HU(hydroxyurea) and Ginseng(*Panax ginseng* extract).

Plasma albumin level is considered as a good indicator for assessment of liver and kidney function as it synthesized by liver and reabsorbed by renal tubules after glomerular filtration, in addition, it is considered one of negative acute phase proteins as its level decreases in response to inflammation (52), so, its level decrement in HU-treated rats may be attributed to the pre-mentioned oxidative hepato-renal affection which could affect hepatic albumin production and increase urinary albumin loss or due to hepato-renal inflammatory state.

Oxidative damage of HU was proved in our study by increased level of MDA (lipid peroxide) and decreased level of GPX in both of hepatic and kidney tissues of HU-treated animals which accompanied by an elevated level of IL6 and TNF alpha in serum of the same animal group. Parallel to this, HU-induced hepato-nephrotoxic damages were affirmed histopathologically by presence of different hepatic and renal lesions that were previously mentioned in HU-treated rat group. Similar lesions were re-

ported by Ahmad et al. (2018) (53). The detected hepato-renal structural distortion may be due to previously mentioned HU-induced oxidative damage. Fortunately, most of biochemical and histopathological alterations caused by HU administration were partially reversed upon co-administration with ginseng. The semiquantitative scoring system demonstrated the protective role of ginseng in HU treated- rats group which was displayed by decreasing the intensity and distribution of the recorded hepatorenal lesions. This effectuation may be attributed to antioxidant activity of *Panax ginseng* that was previously cleared in several studies (54-56). Hepato-renal protective effect of *ginseng* as an antioxidant was previously recorded in different studies (57-60).

Conclusion

Finally, we could conclude that hydroxyurea has an oxidative stress-related deleterious effect on liver and kidneys, in addition to blood cellular components, but, these effects can be partially ameliorated upon administration of ginseng extract as a dietary antioxidant.

Conflict of interest

The authors declare that they have no conflict of interest.

References

1. FDA. Center for Drug Evaluation and Research. Hydrea® packet insert.2010 http://www.accessdata.fda.gov/drugsatfda_docs/label/2010/016295s0401bl.pdf.
2. Marconato L, Bonfanti U, Fileccia I. Unusual dermatologic toxicity of hydroxyurea in two dogs with spontaneously occurring tumors. *J Sm An Pract*2007;48: 514–17.
- 3.Rassnick KM, Al-Sarraf R, Bailey DB, Chretien JD, Phillips B Zwhalen CH. Phase II open-label study of single-agent hydroxyureafor treatment of mast cell tumours in dogs. *Vet Comp Oncol* 2010; 8: 103–11.
4. Bunn HF. Pathogenesis and treatment of sickle cell disease. *N Eng J Med*1997; 337: 762–69.
- 5.Charache S, Terrin ML, Moore RD, Dover GJ, Barton FB, Eckert SV, McMahan RP, Bonds DR. Effect of hydroxyurea on the frequency of painful crises in sickle cell anemia. *N Eng J Med* 1995; 332: 1317–22.
6. Venkayala SL, HargisJC, Woodcock HL.Unlockingthebinding and reaction mechanism of hydroxyurea substrates as biological nitric oxide donors. *J Chem Info Modeling* 2012; 52: 1288–97.
- 7.Silva–Pinto AC, Dias–Carlos C, Saldanha–Araujo F, Ferreira FIS, Palma PVB, Araujo AG et al. Hydroxycarbamide modulates components involved in the regulation of adenosine levels in blood cells from sickle–cell anemia patients. *Ann Hematol* 2014; 93:1457–65.
8. Philips FS, Sternberg SS, Schwartz HS, Cronin AP, Sodergren JE, Vidal PM. Hydroxyurea I. Acute cell death in proliferating tissues in rats.*Cancer Res* 1967; 27: 61–74.
9. Jiang J, Jordan SJ, Barr DP, Gunther MR, Maeda H, Mason RP. In vivo production of nitric oxide in rats after administration of hydroxyurea. *MolPharmacol.* 1997; 52(6):1081–6.
10. Jordan A., Reichard P. Ribonucleotide reductases. *Annu. Rev. Biochem.* 1998;67:71–98.
11. Shao J, Zhou B, Chu B, Yen Y. Ribonucleotide reductase inhibitors and future drug design. *Curr Cancer Drug Targ* 2006; 6:409–31.
12. Saban N, Bujak M. Hydroxyurea and hydroxamic acid derivatives as antitumor drugs. *Cancer ChemotherPharmacol* 2009; 64: 213–21.
13. FDA. Center for Drug Evaluation and Research. Droxia® packet insert. 2012 http://www.accessdata.fda.gov/drugsatfda_docs/label/2012/016295s041s0421bl.pdf.
14. Morton D, Reed L, Huang W, Marcek JM, Austin–LaFrance R, Northcott CA et al. Toxicity of Hydroxyurea in Rats and Dogs.*ToxicolPathol* 2015;43(4):498–512.
- 15.Saalu LC, Osinubi AA, Akinbami AA., YamaOE, Oyewopo AO, Enaibe BU. Moringaoleifera Lamarck (drumstick) Leaf Extract Modulates the Evidences of Hydroxyurea –Induced Testicular Derangement. *Int J Appli Res Natur Products* 2011; 4 (2): 32–45.
16. Wray JD. Methaemoglobinaemia caused by hydroxycarbamide (hydroxyurea) ingestion in a dog. *J Sm An Pract* 2008;49: 211–15.
17. O’Branski EE, Ware RE, Prose NS, Kinney TR. Skin and nail changes in children with sickle cell anemia receiving hydroxyurea therapy. *J Am AcadDermato*2001; 144: 859–61.
18. Vassallo C, Passamonti F, AdrigoM,Nolli G, Mangiacavalli S, Boroni G. Muco–cutaneous changes during long–term therapy with hydroxyurea in chronic myeloid leukemia. *ClinExpDermatol* 2001; 26: 141–48.

19. Imai H, Matsumura N, Yamazaki Y, Kanayama Y, Masuda T, Kuwako T, Kamide Y, Tomizawa T, Matsumoto S, Mitsui T, Kaira K, Ono A, Koga Y, Shibusawa N, Sunaga N, Hisada T, Yokoo H, Yamada M. Hydroxyurea-induced Pneumonitis in a Patient with Chronic Myelomonocytic Leukemia: An Autopsy Case. *Int Med* 2015; 54: 3171–76.
20. Bargagl IE, Palazz IM, Perri F, Torricelli E, Rosi E, Bindi A, Pistolesi M, Voltolini L. Fibrotic Lung Toxicity Induced by Hydroxycarbamide. *In Vivo* 2017; 31(6): 1221–23.
21. Kiefer D., Pantuso T. *Panax ginseng*. *Am Fam Physician*. 2003; 68: 1539–1542.
22. Cho I.H. Effects of *Panax ginseng* in neurodegenerative diseases. *J Ginseng Res*. 2012; 36: 342–53.
23. Ernst E. *Panax ginseng*: an overview of the clinical evidence. *J Ginseng Res*. 2010; 34: 259–63.
24. Park HJ, Kim DH, Park SJ, Kim JM, Ryu JH. *Ginseng* in traditional herbal prescriptions. *J Ginseng Res*. 2012; 36:225–41.
25. Baek SH, Bae ON, Park JH. Recent methodology in ginseng analysis. *J Ginseng Res*. 2012; 36:119–34.
26. Choi KT. Botanical characteristics, pharmacological effects and medicinal components of Korean *Panax ginseng* CA Meyer. *Acta Pharmacol Sin*. 2008; 29:1109–18.
27. Park SH, Oh MR, Choi EK, Kim MG, Ha KC, Lee SK, Kim YG, Park BH, Kim DS, Chae SW. An 8-wk, randomized, double-blind, placebo-controlled clinical trial for the antidiabetic effects of hydrolyzed ginseng extract. *J Ginseng Res*. 2014; 38(4):239–43.
28. Cha KM, Kopalli SR, Han SY, Lee SH, Jeong MS, Cho JY, ha KM, Rajendra KS, Yun HS, Lee SH, Jeong MS, Cho J, Han CG, Lee SH, Kim SN, Kim JC, Kim SK. Korean red ginseng attenuates doxorubicin-induced testicular dysfunction in rats by modulating inflammatory, oxidative, and autophagy responses, *J Funct Food* 2018; 40:736–43.
29. Kim SJ, Kim AK. Anti-breast cancer activity of fine black ginseng (*Panax ginseng* Meyer) and ginsenoside Rg5. *J Ginseng Res* 2015; 39(2):125–34.
30. Chen G, Li H, Zhao Y, Zhu H, Cai E, Gao Y, Liu S, Yang H1, Zhang L. Saponins from stems and leaves of *Panax ginseng* prevent obesity via regulating thermogenesis, lipogenesis and lipolysis in high-fat diet-induced obese C57BL/6 mice. *Food Chem Toxicol* 2017; 106(A) 393–403.
31. Kang S, Min H. *Ginseng*, the 'Immunity Boost': the effects of *Panax ginseng* on immune system. *J Ginseng Res* 2012; 36:354–68.
32. Kim SJ, Kim AK. Anti-breast cancer activity of fine black ginseng (*Panax ginseng* Meyer) and ginsenoside Rg5. *J Ginseng Res* 2015; 39(2):125–34
33. Kalkan Y, Kapakin KA, Kara A, Atabay T, Karadeniz A, Simsek N, Karakus E, Can I, Yildirim S, Ozkanlar S, Sengul E. Protective effect of *Panax ginseng* against serum biochemical changes and apoptosis in kidney of rats treated with gentamicin sulphate. *J Mol Hist* 2012; 43(5):603–13.
34. Nair AB, Jacob S. A simple practice guide for dose conversion between animals and human *J Basic Clin Pharma* 2016; 7: 27–31.
35. El-Bayomi K M, Saleh A A, Awad A, El-Tarabany M S, El-Qaliouby H S, Afifi M, El-Komy S, Essawi W M, Almadaly E A, El-Magd M A. Association of CYP19A1 gene polymorphisms with anoestrus in water buffaloes, *Reproduction, Fertility and Development* 2018; 30(3): 487–97.
36. SAS. Statistical analysis system. SAS User's Guide, SAS incorp Inst 2004.
37. Schecheter AN, Rodgers GP. Sick cell anemia—basic researches reach the clinic. *Eng J Med* 1995; 332: 1372–74.
38. Liebelt EL, Balk SJ, Faber W, Fisher JW, Hughes CL, Lanzkron S M. et al. NTP-CERHR expert panel report on the reproductive and developmental toxicity of hydroxyurea. *Birth Defects Res* 2007; 80: 259–366.
39. Ahmad ME, Shadab GG, Azfer, MA. Effect of oxymetholone on SCE frequency in human lymphocyte chromosomes in vitro. *Teratogen Carcinog Mutagen* 2003; 1: 267–72.
40. Johnson C, Telen MJ. Adhesion Molecules And Hydroxyurea In The Pathophysiology Of Sick Cell Disease. *Haematologica* 2008; 93: 481–85.
41. Iyamu EW, Fasold H, Roa D, del Pilar Aguinaga M, Asakura T, Turner EA. Hydroxyurea-induced oxidative damage of normal and sickle cell hemoglobins in vitro: amelioration by radical scavengers. *J Clin Lab Anal*. 2001; 15: 1–7.
42. Vassort F, Winterholer M, Frindel E, Tubiana M. Kinetic Parameters of bone marrow stem cells Using in vivo Suicide by Tritiated Thymidine or by Hydroxyurea. *Blood* 1973; 41(6): 789–96.
43. Malec J, Przybyszewski MW, Grabarczyk M, Sitarska, E. Hydroxyurea has the capacity to induce damage to human erythrocytes which can be modified by radical scavengers. *Biochem Biophys Res Commun* 1984; 120:566–73.

44. Farber E, Baserga R. Differential Effects of Hydroxyurea on Survival of Proliferating Cells in Vivo. *Cancer Res.* 1969; 29(1):136–9.
45. Sakano K, Oikawa S, Hasegawa K, Kawanishi S. Hydroxyurea Induces Site-specific DNA Damage via Formation of Hydrogen Peroxide and Nitric Oxide. *Jpn. J. Cancer Res.* 2011; 92: 1166–74.
46. Nagai T, Tarumoto T, Miyoshi T, Ohmine K, Muroi K, Komatsu N, Sassa S, Ozawa K. Oxidative Stress is Involved in Hydroxyurea-induced Erythroid Differentiation. *British J. of Haematol* 2003; 121: 657–61.
47. Cokic VP, Smith RD, Beleslin-Cokic BB, Njoroge JM, Miller JL, Gladwin MT, Schechter AN. Hydroxyurea induces fetal hemoglobin by the nitric oxide-dependent activation of soluble guanylyl cyclase. *J Clin Invest* 2003; 111(2): 231–9.
48. Przybyszewski WM, Malec J. Protection against hydroxyurea-induced cytotoxic effects in L5178Y cells by free radical scavengers. *Cancer Lett* 1982; 17: 223–8.
49. Grabarczyk M, Przybyszewski WM, Kwiatkowska J, Sitarska E, Malec J. Alteration in lysosome supravital staining as marker of hydroxyurea-induced cytotoxicity and its modification by radical scavengers in L5178Y cells in culture. *Neoplasma* 1983; 30:541–6.
50. Yarbrow JW. Mechanisms of action of hydroxyurea. *Semin Oncol* 1992; 19:1–10.
51. Koviach P. Hydroxyurea (therapeutics and mechanism): Metabolism, carbamoylnitroso, nitroxyl, radicals, cell signaling and clinical applications. *Med Hypotheses* 2011; 76: 24–31.
52. Latimer KS, Mahaffey EA, Prasse KW. *Veterinary Laboratory Medicine, Clinical Pathology*. 4th ed. Iowa State Press. USA 2003.
53. Ahmad MF, Ansari MO, Jameel S, Wani AL, Parveen N, Siddique HR et al. Protective Role of Nimbolide against Chemotherapeutic Drug Hydroxyurea Induced Genetic and Oxidative Damage in an Animal Model. *Environ Toxicol Pharmacol* 2018; 60: 91–9.
54. Choe WCS, Chung W, Lee SKW, Leung AWN, Cheng CHK, Yue KKM. Ginsenoside Re of Panax Ginseng possesses significant antioxidant and antihyperlipidemic efficiencies in streptozotocin-induced diabetic rats. *Euro J Pharma* 2006; 550: 173–9.
55. Swaress FAR. Effect of Ginseng Extract Supplementation on Renal Functions in Diabetic Rats. *J of Agri Sci* 2011; 3(2): 17–31.
56. El-Denshary ES, Al-Gahazali MA, Mannaa FA, Salem HA, Hassan NS, Abdel-Wahhab MA. Dietary honey and ginseng protect against carbon tetrachloride-induced hepato-nephrotoxicity in rats. *Exp Toxicol Pathol* 2012; 64(7–8): 753–60.
57. Zhu H, Long MH, Wu J, Wang MM, Li XY, Shen H et al. Ginseng alleviates cyclophosphamide-induced hepatotoxicity via reversing disordered homeostasis of glutathione and bile acid. *Sci Rep.* 2015; 5:17536.
58. Qi ZL, Wang Z, Li W, Hou JG, Liu Y, Li XD et al. Nephroprotective Effects of Anthocyanin from the Fruits of Panax ginseng (GFA) on Cisplatin-Induced Acute Kidney Injury in Mice. *Phytother Res* 2017; 31(9):1400–9.
59. Wang W, Wang S, Liu J, Cai E, Zhu H, He Z et al. Sesquiterpenoids from the root of Panax Ginseng protect CCl₄-induced acute liver injury by anti-inflammatory and anti-oxidative capabilities in mice. *Biomed Pharmacother* 2018; 102: 412–19.
60. Zhou YD, Hou JG, Liu W, Ren S, Wang YP, Zhang R et al. 20(R)-ginsenoside Rg₃, a rare saponin from red ginseng, ameliorates acetaminophen-induced hepatotoxicity by suppressing PI3K/AKT pathway-mediated inflammation and apoptosis. *Int Immunopharmacol* 2018; 59: 21–30.