

Ovarian Cancer Diagnosis and Treatment in a Geriatric Bitch: Challenges in Treating an Elder pet Aggravated by COVID-19 Pandemic Restrictions

Key words

canine ovarian cancer;
COVID-19 pandemic
lockdown;
metastatic adenocarcinoma;
ovariohysterectomy;
pulmonary metastasis

Beatriz Scabelo Tessaro¹, Raquel Aufran Theme², Rafaela Ferreira dos Santos⁴, Marcus de Freitas Ferreira³, Juliana da Silva Leite^{4,5}, Camila Barbosa Amaral^{5*}

¹Veterinary Medicine Graduation Course, Agricultural Sciences and Engineering Center, Espírito Santo Federal University, Alto Universitário, s/n, 29500-000, Alegre, ES, ²Veterinary Medicine Graduation Course, Veterinary Faculty, Fluminense Federal University, Av. Ary Parreiras, n. 570, 24230-320, Niterói, RJ, ³Veterinary Medicine Department, Agricultural Sciences and Engineering Center, Espírito Santo Federal University, Alto Universitário, s/n, 29500-000, Alegre, ES, ⁴Veterinary Medicine Post-Graduation Program (Animal Clinics and Reproduction), Veterinary Faculty, Fluminense Federal University, Av. Ary Parreiras, n. 570, 24230-320, Niterói, RJ, ⁵Veterinary Pathology and Clinics Department, Veterinary Faculty, Fluminense Federal University, Av. Ary Parreiras, n. 570, 24230-320, Niterói, RJ, Brazil

*Corresponding author: cbamaral@id.uff.br

Abstract: Ovarian tumors are considered rare in dogs but pose a diagnostic challenge, requiring oncological expertise to establish diagnosis and accurate treatment. Diagnostic imaging is crucial to cancer diagnosis and treatment follow-up but, as in Medicine, this service was impacted by quarantine imposed by COVID-19 pandemic. This report aimed to describe a senior canine patient diagnosed with ovarian adenocarcinoma in a Brazilian country town during COVID-19 lockdown, evaluating the decision-making process in the absence of a veterinary oncology specialist, complicated by pandemic restrictions. A 15-year-old, nonspecific breed, intact bitch presented apathy and emesis. Abdominal palpation revealed increased epigastric volume. Ultrasonography suggested tumoral mass of unknown origin. Exploratory laparotomy was performed and a unilateral ovarian mass was removed. Patient recovered well from surgery. Histopathological evaluation revealed ovarian adenocarcinoma with lymphatic vascular invasion. No further treatment was indicated. Semesterly revisions were scheduled but metastasis developed in less than a year, after first revision. By this time, thoracic radiography was unavailable in owner's town, impairing metastasis screening and prognosis. Chemotherapy was offered only after metastasis detection but was declined by the owner. Patient was lost in follow-up. This present case illustrates the importance of a prompt diagnosis and suitable treatment for ovarian cancer-bearing patients based on veterinary oncology expertise. It also emphasizes how pandemic lockdown prejudicated imaging exam availability, especially in country towns, similar to what was observed in human patients, reflecting an undeniable One Health issue.

Received: 29 July 2025

Accepted: 9 December 2025

Introduction

Ovarian tumors are considered rare in dogs and represent 0,5 to 1,2% of all neoplasms, reaching up to 6% in intact bitches (1). They are divided according to their original ovarian tissue in epithelial (tubular and papillary adenocarcinomas, carcinoma, adenoma and cystadenoma), germ cells (dysgerminoma and teratoma), sex cord stromal (granulosa cell tumor, thecoma and

luteoma) and mesenchymal tumors (e.g.: hemangiosarcoma, leiomyoma), this last ones with sparse cases in literature (1,2).

Epithelial ovarian tumors are the most frequent, approximately 50% of reported ovarian tumor cases in bitches, and half of the malignant types (adenocarcinoma and carcinoma) will metastasize to lymph nodes and abdominal organs via tumor cell implantation, a process known as carcinomatosis (1,2). Carcinomas can begin insidiously and grow up to palpable abdominal

mass (1,3). Abdominal ultrasound is capable of identifying such mass and effusion associated with carcinomatosis, and thoracic radiography is indicated for metastatic disease identification (1,4). Ovariohysterectomy is the treatment of choice although adjuvant chemotherapy can be adopted in an attempt to prevent tumor progression (1,3). Definitive diagnosis is determined by histopathological evaluation of excised ovarian mass (1,2,3,4).

Routine early-age neutering adopted in many countries prevents ovarian tumor development in bitches (1,5,6). Even nowadays, many owners are insecure about preventive neutering, which aims to avoid reproductive system cancer in addition to birth control (5,6).

Companion animal oncology has evolved rapidly in recent decades and new therapies have emerged for treating dogs and cats with cancer. Nevertheless, veterinary oncology specialization is required to adequately approach a cancer-bearing pet, considering not only the patient's health but also the owner's own experience with cancer and the animal-human bond (7). The vast majority of veterinary specialists remain in the urban centers, leading to a shortage in rural and remote areas (8,9). In addition, corporations focusing in companion animals practice are often established in urban areas (9). Therefore, facilities such as veterinary laboratories and diagnostic imaging centers for pets are not often found in the countryside (9), what can compromise diagnostic investigation in dogs and cats living in these areas.

This countryside panorama was worsened during COVID-19 pandemic, when treating oncological patients, whether humans or pets, has become a crossroads. Worldwide decreed lockdown led to oncological treatment delays and postponed routine and screening tests for early-stage cancer and metastasis detection in human patients (10,11). This situation yielded health and economic impacts: an increase in late-stage cancer diagnosis, leading to poorer prognosis, and health service demand, with a huge expense increment (10,11).

This report aims to describe the case of a female dog diagnosed with ovarian cancer, at the beginning of COVID-19 pandemic, in a countryside town. Clinical course, imaging diagnosis, surgery and treatment options in the absence of a veterinary oncology specialist are described in addition to oncological geriatric patient approach complications as well as all limitations imposed by COVID-19 pandemic lockdown. The importance of a timely-manner treatment decision in oncological patient is depicted under One Health aspects.

Case Presentation

A 15-year-old intact female dog of no specific breed (NSB), weighing 14.5 kg was presented to private clinical attendance. Two days before, the bitch had an emesis episode, was apathic and hyporectic. On the next dawn, many emesis episodes followed and by morning the dog presented hematochezia.

Table 1: Complete blood count (CBC) results; dog, female, NSB, 14y, with ovarian adenocarcinoma: CBC parameters revealed mild neutrophilia (a) and marked lymphopenia (b) on relative values (asterisk)

Variable	Value	Reference Value*
RBC	6.81 x 10 ¹² /mL	5.5–8.5 x 10 ¹² /mL
HGB	14.00 g/dl	12-18 g/dl
HCT	42.80 %	37-55%
MCV	62.84 fl	60-77 fl
MCHC	32.71%	32-36%
WBC	12460/μl	6000 – 17000/μl
Bands	2% (249)	0-2%
Neutrophils	90% (11214) ^a	58-87%
Lymphocytes	5% (623) ^b	12-30%
Monocytes	3% (374)	3-10%
Basophils	0	Rare
Eosinophils	0	2-10%
Platelets	282000/μl	175 – 500000/μl

RBC: total red blood cells; HGB: hemoglobin; HCT: hematocrit; MCV: mean corpuscular volume; MCHC: mean corpuscular hemoglobin concentration; WBC: total white blood cells. *Reference values provided by the private laboratory

Table 2: Serum biochemistry results; dog, female, NSB, 14y, with ovarian adenocarcinoma: parameters within normal range, except for alanine aminotransferase (ALT) (a) and alkaline phosphatase (ALP) (b), and reference values

Variable	Value	Reference Value*
Urea	36.0 mg/dL	20-50 mg/dL
Creatinin	0.64 mg/dL	0.5-1.6 mg/dL
AST	87.0 mg/dL	10-88/ul
ALT	307.8 mg/dL ^a	10-88/ul
ALP	222.0 mg/dL ^b	20-156/ul
GGT	6.0 mg/dL	≤ 10 mg/dL

AST: aspartate aminotransferase; ALT: alanine aminotransferase; ALP: alkaline phosphatase; GGT: gamma-glutamyl transferase. *Reference values provided by the private laboratory

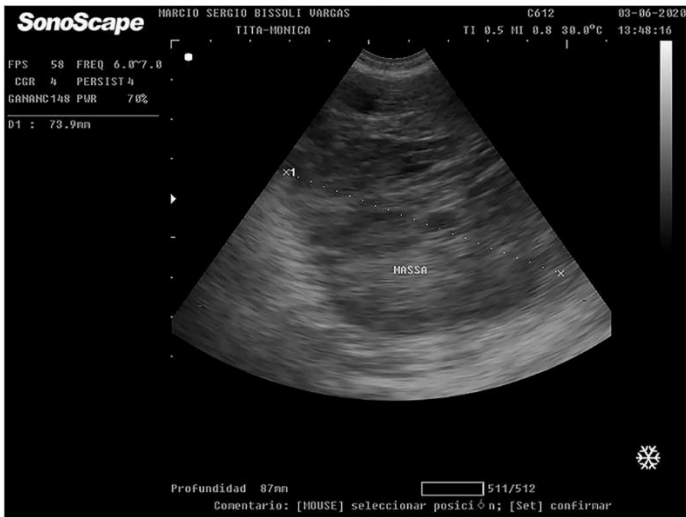


Figure 1: Dog, female, NSB, 14y, abdominal ultrasound image: well-defined, heterogeneous mass (*massa*) on the epigastric region, measuring 7,39 cm long

On clinical examination, grade 2 dehydration (12) and swollen popliteal and submandibular lymph nodes were noticed. Abdominal palpation revealed an increased epigastric volume, suggesting tumoral mass. Clinical suspicion was pyometra or neoplasia.

Abdominal ultrasonography, complete blood count (CBC) and serum biochemistry were requested. Ultrasound revealed a heterogeneous tumoral mass, 7,39 cm wide (Fig. 1). No specific origin was mentioned. CBC values revealed mild neutrophilia and marked lymphopenia on relative values (Table 1). Serum alanine aminotransferase (ALT) and alkaline phosphatase (ALP) showed increased values (Table 2). CBC and serum biochemistry analyses were performed by automated hematological equipment. Abdominal ultrasound was performed by SonoScape® equipment.

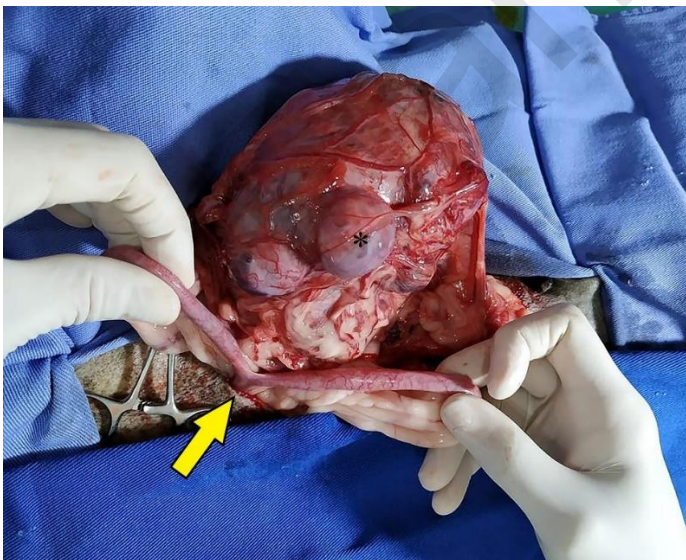


Figure 2: Dog, female, NSB, 14y, abdominal exploratory laparotomy: tumoral mass adhered to the right ovary site (asterisk). Uterine horn bifurcation is exposed (arrow)

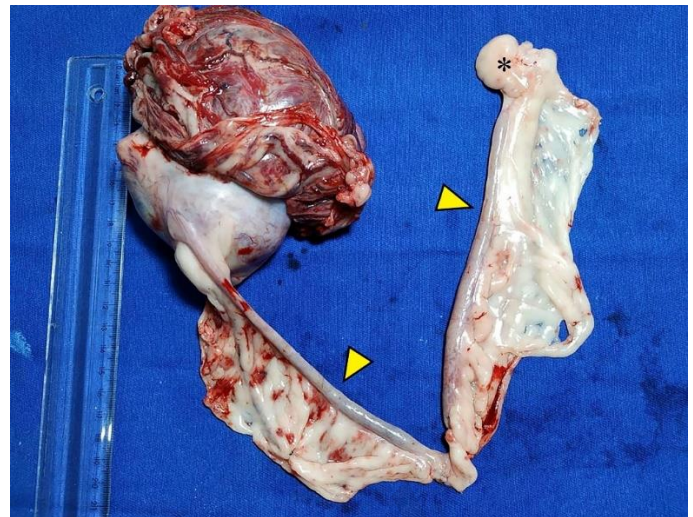


Figure 3 Dog, female, NSB, 14y, surgically excised piece: macroscopically normal uterine horns (arrow heads) with left ovary pouch (asterisk) and right ovarian mass (papillary adenocarcinoma), red and well vascularized

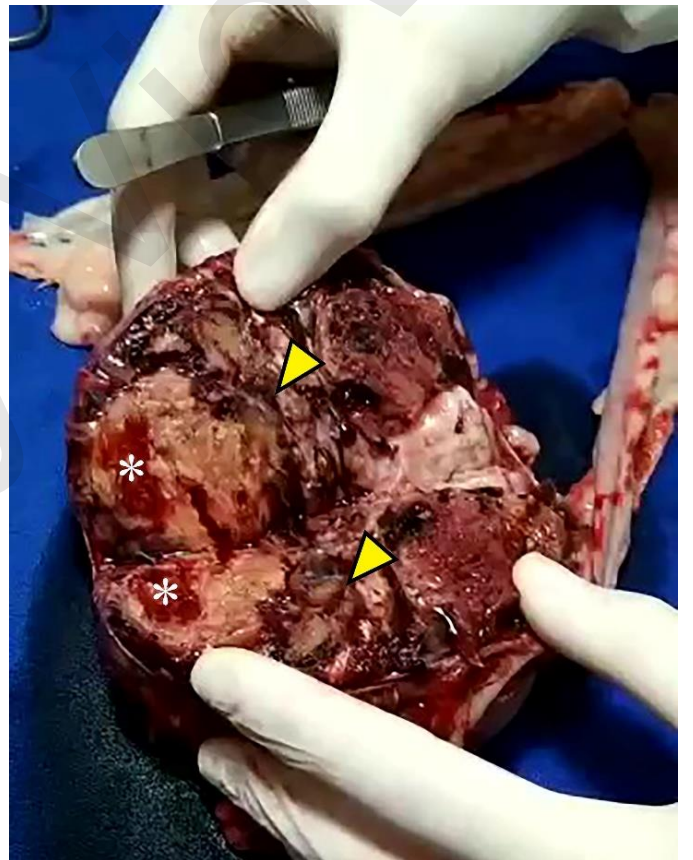


Figure 4: Dog, female, NSB, 14y, surgical excised piece: tumoral mass cut surface presenting different areas of multinodular tumoral tissue formation (pale, yellow and reddish tissue), with hemorrhage (asterisk), necrotic areas (arrow heads) and some vascular spaces, features commonly associated with malignant neoplasms

Patient was hospitalized for three days, under venous fluid therapy (Lactate Ringer's solution, intravenously) and antiemetic medication (ondasentron, 0,5 mg/kg, BID, IV). An exploratory laparotomy was scheduled. Surgical approach was performed

by pre-retro-umbilical incision. Abdominal access revealed a tumoral mass adhered to right ovary (Fig. 2). Ovariohysterectomy (OHE) was performed (13) with owner consent. Surgery was concluded without further intercurrent. Postoperative prescriptions included antibiotics (enrofloxacin, 5 mg/kg, BID, PO, 10 days), anti-inflammatory (meloxicam, 0,1 mg/kg, SID, PO, 3 days) and antiemetic medication (ondansetron, 0,5 mg/kg, BID, PO, 5 days) and wound management (allantoin-based moisturizing ointment, topic, SID, 7 days). Patient recovered well with medical discharge 10 days after surgery.

Excised piece was sent to histopathological evaluation. On macroscopic analyses, ovarian mass was 12 cm wide, 13,5 cm long and 6,9 cm depth, with well-defined margins, red color and well vascularized. Left ovary and uterine horns were macroscopically normal (Fig. 3). The cut surface of the mass showed pale, yellow and red colored multinodular tissues with hemorrhage, necrosis and vascular spaces (Fig. 4). Samples were fixed in 10% formalin and submitted to routine histological process in alcohol and xylene passages until paraffin embedding and microtomy. Histopathological evaluation of hematoxylin-eosin-stained sections revealed high-density cellular epithelial neoplastic cells, with solid areas accompanied by papillae formation. Neoplastic cells presented scarce basophilic cytoplasm and prominent nucleolus. Moderate to intense pleomorphism was noticed. Up to six mitosis figures were observed under high power field (HPF). Lymphatic vascular invasion was noticed. An ovarian papillary adenocarcinoma diagnosis was established (2).

Fifteen days after surgery, patient was well, normophagic and normodipsic, going for daily walks, without any apathy signs. Veterinary clinical recommendation was for clinical follow-up every six months for thoracic radiography, abdominal ultrasonography for metastasis investigation, besides CBC and serum biochemistry.

On the first revision, six months later, aforementioned exams showed no alterations. Before the second revision, the owner noticed subcutaneous nodules in the thoracic region. Thoracic radiography was requested, but it was unavailable in the owner's rural town due to the COVID-19 pandemic lockdown. Therefore, the examination was delayed. On clinical return, a few weeks later, follow-up exams were performed: CBC showed no alterations and thoracic radiography revealed multiple radiopaque pulmonary nodules. On this occasion, palliative chemotherapy was indicated to restrain metastasis evolution and improve patient overall survival. The owner declined chemotherapy due to dog's advanced age and patient was lost in follow-up.

Discussion

This reported patient was an intact, senior bitch, conditions that predispose canine ovarian tumor development (1, 2, 14). No adenocarcinoma was found in ovaries from clinically healthy bitches submitted to elective OHE in a previous report (5).

Mean age of these bitches was 5,8 years-old and the oldest record was 8,0 years-old (5). Another study specifically focused on malignant ovarian tumors: mean age of the included dogs was 12 years, ranging from 7 to 15 years (3). More recently, a retrospective study found five adenocarcinomas out of 35 ovarian tumors (benign and malignant), in bitches with mean age of 9,6 years (4). Nonspecific clinical signs such as hyporexia and apathy are commonly described, followed by weight loss and ascites (1, 3); the latter did not occur in the patient presented. This patient presented with emesis, accompanied by ALT and AP alterations, indicating carcinomatosis of the abdominal organs. Ovarian tumors are initially insidious but might grow to become a palpable abdominal mass (1, 4, 5, 15), as presented by this patient.

Abdominal ultrasonography (US) is adamant to elucidate ovarian masses (1, 4, 16), although in the present case, mass origin was not identified by the evaluator. Ovarian adenocarcinoma does not usually alter blood or serum parameters, as it is not hormone-producing (1, 2). This patient's increased ALT and ALP may be related to anorexia, gastrointestinal symptoms, or carcinomatosis.

OHE is the treatment of choice for ovarian cancers in dogs (1, 4, 5). Despite being senior, patient evolved well after surgery, putting down the myth of old dogs being inoperable patients.

Surgery revealed a unilateral ovarian mass, with no macroscopic sign of carcinomatosis or ascites. Unilateral ovarian adenocarcinoma is considered uncommon (2, 3, 8). Ovarian carcinomas can produce abdominal carcinomatosis and ascites (2, 14). Neither processes were identified on US nor OHE. Likewise, pyometra and/or cystic endometrial hyperplasia usually accompany ovarian tumors (1, 5, 16). Although not histologically evaluated, uterus was macroscopically normal, even for a geriatric intact dog.

Tumor macroscopy evaluation indicated many malignant features, with US correspondence. Large ovarian tumors are more likely to be malignant (2, 4). Median diameters of 3,5 cm (17) and 6,9 cm (3), with maximum measures of 8,0 cm and 19,0 cm, respectively, have been reported for malignant ovarian tumors. Ovarian mass described here was within this range. Solid ovarian masses are often related to malignancy on US and macroscopy examination, as in the present case, while cystic lesions tend to be benign (4, 16). Haemorrhage and necrosis are common macroscopic features of malignant neoplasms and contribute to heterogeneous echotexture, along with multinodular tumour tissue formation, on ultrasound (1, 3, 4, 6, 22), as seen in this case. Unfortunately, these malignant features were overlooked by the general practitioner at the time of surgery.

Tumor etiology is defined by histopathological evaluation and carcinoma is the most frequent canine ovarian epithelial tumor (1, 2, 4, 16). An extremely important information was overlooked in the histopathological report: lymphatic vascular invasion by neoplastic cells was observed. This is a morphological feature of metastatic process in progress (2, 3). Hence, according to the World Health Organization (WHO) TNM staging

scheme for canine ovarian tumors (3), although regional lymph nodes were not evaluated, this finding was enough to categorize this patient as N1 (positive for lymph node metastasis), with poor prognosis. As a unilateral tumor, T category was classified as T1 and since no distant metastasis was observed, M category was M0, at the time of diagnosis.

In this present case, oncological indication was for monthly or quarterly clinical revision (1), reinforced by lymphatic cellular invasion evidence, instead of semesterly. Due to COVID-19 pandemic and lockdown, human oncological treatment protocols were revised, to balance patient exposure risk to SARS-CoV-2 and adequate metastasis screening intervals (10, 18). Delaying revisions were not discussed with the dog's owner and it was not possible to determine if semesterly revisions were chosen based on pandemic restrictions or lack of oncological knowledge.

Regional and distant metastases are frequent on adenocarcinomas, especially to regional lymph nodes (1, 2, 3). Carcinomatosis is more common in ovarian bilateral tumors (1, 2, 14, 17) and was not observed in this case. Peritoneal and pleural neoplastic implants are considered distant metastases in ovarian cancer (3, 14) but might be difficult to diagnose even under computed tomography (CT) (14, 15), increasing the importance of a thorough macroscopy evaluation during surgery in search for these lesions (15).

Despite radiography low sensibility, it is still the most commonly used imaging modality for pulmonary evaluation in oncological companion animals (16, 19) since lungs are among the most cited sites for malignant neoplasm distant metastasis (1, 2). However, in canine (1, 3, 15, 17) and human (20) ovarian cancer, pulmonary metastasis is rarely described. CT is more sensitive for pulmonary nodules but it has a higher cost and lower availability when compared to radiography (14, 15, 19, 21), especially in Brazil.

No further oncological treatment besides surgery was offered to presented patient and metastasis developed quickly, in less than a year. This phenomenon is identified in many cancers as metastatic progression suppression by primary site or concomitant tumor resistance (22, 23). In presented case, adjuvant chemotherapy (CTx) was recommended because of lymphatic vascular invasion (3). CTx was indicated as complimentary treatment only after subcutaneous nodule detection, which worsened patient's prognosis (1, 2, 3). Since no further US evaluation or nodule cytology was performed, it is not possible to affirmatively correlate these nodules with ovarian cancer in this patient. Although very rare, cutaneous metastasis is described in women with ovarian carcinoma (24), but no such canine case was found.

Chemotherapy was declined by the owner, concerned with dog's quality of life. Such preoccupation is frequent in veterinary geriatric patients with cancer, mirroring human disease and its adverse reactions (7). However, new treatment modalities aimed at metastasis control, such as metronomic chemotherapy, are already available for companion animals, preserving quality of life and increasing overall survival time (25, 26, 27).

Currently, many veterinary clinicians feel unable to proceed with oncological treatments, especially chemotherapy (8). Another decision-making complication in this case is oncology specialist availability on the country side of a continental country such as Brazil (8). In addition, most of the time, companion animal oncological treatment is not affordable to the vast majority of population, even more so during COVID-19 pandemic which has led to an increase in unemployment rates worldwide (28). The same scenario regarding oncological treatment expense concerns during pandemic was described in Medicine (10, 28, 29).

Another difficulty observed in this case was diagnostic imaging realization. This veterinary service may again be deficient on the country side (9). COVID-19 pandemic lockdown contributed to diagnosis delays and treatment interruptions in thousands of cancer cases worldwide (10, 11, 29). During quarantine, routine medical appointments and exams, which often identify pre-tumoral or initial malignant lesions, were left aside (10, 11, 29) although they were still available as essential services by Brazilian national law (30). Such an unprecedented situation was expected to impair health systems, increasing the number of newly diagnosed advanced-stage cancer patients and compromising an already debilitated health budget (10, 29). The same impact was expected and is by now observed in Veterinary Medicine routine, reflecting One Health issues.

Conclusions

The present case illustrates the importance of a timely diagnosis and adequate treatment for oncological companion animals, regardless of age. Histopathological analysis is adamant for ovarian tumor identification, such as adenocarcinoma and can also inform metastatic progression such as lymphatic vascular invasion. Adjuvant chemotherapy is indicated in such cases to prevent rapid metastasis dissemination and improve overall survival time. Unfortunately, lack of veterinary oncology specialists is a reality, mostly in the countryside of Brazil. Follow-up imaging exams are important for staging bitches with ovarian adenocarcinoma but this service was dramatically impacted by COVID-19 pandemic lockdown, similar to what occurred in oncological human patients, under a One Health system view.

Acknowledgements

Ethics Approval and Consent to Participate: An Ethics Committee on the Use of Animals approval was waived since the presented case does not include animal experimentation. Informed consent obtained from owner.

Consent for publication: Written informed consent was obtained from the participant (dog owner) for publication of this case report and accompanying images.

Competing Interests: The authors declare that they have no competing interest.

Funding: This research did not receive any specific grant from funding agencies in the public, commercial, or not-for-profit sectors.

List of Abbreviation

COVID-19 – coronavirus disease (2019), OHE - ovariohysterectomy, NSB – no specific breed, CBC – complete blood count, ALT - alanine aminotransferase, ALP - alkaline phosphatase, HPF – high power field, US - ultrasonography, WHO – World Health Organization, TNM – tumor node metastasis, SARS-CoV-2 - severe acute respiratory syndrome coronavirus 2, CTx - chemotherapy, CT – computed tomography

References

1. Saba CF, Lawrence JA. Tumors of the Female Reproductive System. In: Vail DM, Thamm DH, Liptak JM, eds. *Withrow and MacEwen's Small Animal Clinical Oncology*. Missouri: Elsevier, 2020: 597-603.
2. Agnew DW, MacLachlan NJ. Tumors of the Genital Systems. In: Meuten DJ, ed. *Tumors in Domestic Animals*. New Jersey: Wiley-Blackwell, 2020: 689-722.
3. Goto S, Iwasaki R, Sakai H, Mori T. A retrospective analysis on the outcome of 18 dogs with malignant ovarian tumours. *Vet Comp Oncol*, 2021; 19: 442-450. doi: <https://doi.org/10.1111/vco.12639>
4. Troisi A, Orlandi R, Vallesi E, et al. Clinical and ultrasonographic findings of ovarian tumours in bitches: A retrospective study. *Theriogenology*. 2023; 210: 227-233. doi: <https://doi.org/10.1016/j.theriogenology.2023.07.020>.
5. Maya-Pulgarin D, Gonzalez-Dominguez MS, Aranzazu-Taborda D, Mendoza N, Maldonado-Estrada JG. Histopathologic findings in uteri and ovaries collected from clinically healthy dogs at elective ovariohysterectomy: a cross-sectional study. *J Vet Sci*. 2017; 18: 407-414. doi: <https://doi.org/10.4142/jvs.2017.18.3.407>.
6. Arlt S, Wehrend A, Reichler IM. Kastration der Hündin – neue und alte Erkenntnisse zu Vor- und Nachteilen [Neutering of female dogs - old and new insights into Pros and Cons]. *Tierarztl Prax Ausg K Kleintiere Heimtiere*. 2017; 45: 253-263. German. doi: <https://doi.org/10.15654/TPK-170322>.
7. Vail DM, Thamm DH, Liptak JM. Introduction. In: Vail DM, Thamm DH, Liptak JM, eds. *Withrow and MacEwen's Small Animal Clinical Oncology*. Missouri: Elsevier; 2020: xxi-xx.
8. Lloyd JW, Greenhill LM. The veterinary specialist faculty shortage: it is not all about the numbers. *Vet Ophthalmol*. 2025; 1-5. doi: [10.1111/vop.70034](https://doi.org/10.1111/vop.70034).
9. Federation of Veterinarians of Europe. Shortage of veterinarians in rural and remote areas – Summary Report. Published in July, 2020. Available at: https://2020.fve.org/cms/wp-content/uploads/Shortage_Vets_Rural_Areas10July2020.pdf
10. Rosas TV, Cazap E, Delgado L, et al. Social distancing and economic crisis during COVID-19 pandemic reduced cancer control in Latin America and will result in increased late-stage diagnoses and expense. *JCO Glob Oncol*. 2021; 7: 694-703. doi: <https://doi.org/10.1200/GO.21.00016>.
11. Herrera CA, Kerr AC, Dayton JM, Kakietek JJ. Healthcare service disruption in 14 Latin American and Caribbean countries during the COVID-19 pandemic: Analysis of household phone surveys, 2020-2021. *J Glob Health*. 2023; 13: 06023. doi: [10.7189/jogh.13.06023](https://doi.org/10.7189/jogh.13.06023).
12. Rudloff E. Assessment of hydration. In: Silverstein DC, Hopper K, eds. *Small animal critical care medicine*. St Louis: Elsevier Saunders; 2015: 307–311.
13. Romagnoli S, Krekeler N, de Cramer K, Kutzler M, McCarthy R, Schaefer-Somi S. WSAVA guidelines for the control of reproduction in dogs and cats. *J Small Anim Pract*; 2024; 65: 424-559. doi: [10.1111/jsap.13724](https://doi.org/10.1111/jsap.13724).
14. Manfredi M, Morabito S, Fournier Q, Panopoulos I, Thierry F, Schwarz T, Lopez C, et al. Computed tomographic findings in dogs with ovarian tumors: A tortuous ovarian artery consistently identifies ovarian origin in complex abdominal masses. *Vet Radiol Ultrasound*. 2025; 66: e13476. doi: [10.1111/vru.13476](https://doi.org/10.1111/vru.13476).
15. Rowan C, Cuddy L, Bryan J, Shiel R, Hoey S. Imaging Diagnosis-Computed Tomography findings in a case of metastatic ovarian adenocarcinoma in a dog. *Vet Radiol Ultrasound*. 2017; 58: E60-E63. doi: <https://doi.org/10.1111/vru.12431>.
16. Russo M, England GCW, Catone G, Marino G. Imaging of canine neoplastic reproductive disorders. *Animals (Basel)*. 2021; 11: 1213. doi: <https://doi.org/10.3390/ani11051213>.
17. Kita C, Chambers JK, Tanabe M, Irie M, Yamasaki H, Uchida K. Immunohistochemical features of canine ovarian papillary adenocarcinoma and utility of cell block technique for detecting neoplastic cells in body cavity effusions. *J Vet Med Sci*. 2022; 84: 406-413. doi: <https://doi.org/10.1292/jvms.21-0633>.
18. Mukherjee A, Shammas N, Xu L, et al. Impact of the Coronavirus Disease 2019 pandemic on neoadjuvant chemotherapy use in patients diagnosed with epithelial type ovarian cancer. *Front Oncol*. 2024; 14: 1290719. doi: <https://doi.org/10.3389/fonc.2024.1290719>.
19. Lamb CR, Whitlock J, Foster-Yeow ATL. Prevalence of pulmonary nodules in dogs with malignant neoplasia as determined by CT. *Vet Radiol Ultrasound*. 2019; 60: 300-305. doi: <https://doi.org/10.1111/vru.12723>.
20. Berek JS, Renz M, Kehoe S, Kumar L, Friedlander M. Cancer of the ovary, fallopian tube, and peritoneum: 2021 update. *Int J Gynaecol Obstet*. 2021; 155(Suppl 1): 61-85. doi: <https://doi.org/10.1002/ijgo.13878>.
21. Greco A, Meomartino L, Gnudi G, Brunetti A, Di Giancamillo M. Imaging techniques in veterinary medicine. Part II: Computed tomography, magnetic resonance imaging, nuclear medicine. *Eur J Radiol Open*. 2023; 10: 100467. doi: <https://doi.org/10.1016/j.ejro.2022.100467>.
22. Hanin L, Rose J. Suppression of metastasis by primary tumor and acceleration of metastasis following primary tumor resection: A Natural Law? *Bull Math Biol*. 2018; 80: 519-539. doi: <https://doi.org/10.1007/s11538-017-0388-9>.
23. Kallis MP, Maloney C, Blank B, Soffer SZ, Symons M, Steinberg BM. Pharmacological prevention of surgery-accelerated metastasis in an animal model of osteosarcoma. *J Transl Med*. 2020; 18: 183. doi: <https://doi.org/10.1186/s12967-020-02348-2>.
24. Li J, Cao C, Liu P, Yan Z, Xing D, Liu A. Cutaneous metastasis of carcinomatous component of ovarian carcinosarcoma: A case report and review of the literature. *Diagn Pathol*. 2022; 17: 76. doi: <https://doi.org/10.1186/s13000-022-01256-x>.
25. Machado MC, Yamamoto PA, Pippa LF, et al. Pharmacokinetics of Carboplatin in Combination with Low-Dose Cyclophosphamide in Female Dogs with Mammary Carcinoma. *Animals (Basel)*. 2022; 12: 3109. doi: <https://doi.org/10.3390/ani12223109>.
26. Milevoj N, Nemeč A, Tozon N. Metronomic Chemotherapy for Palliative Treatment of Malignant Oral Tumors in Dogs. *Front Vet Sci*. 2022; 9: 856399. doi: <https://doi.org/10.3389/fvets.2022.856399>.
27. Jung MJ, Yoon KY, Kim YM, et al. Long-term adjuvant metronomic chemotherapy in a dog with recurrent maxillofacial osteosarcoma. *Vet Med (Praha)*. 2023; 68: 225-230. doi: <https://doi.org/10.17221/43/2022-VETMED>
28. Kirby A, Drummond FJ, Lawlor A, Murphy A. Counting the social, psychological, and economic costs of COVID-19 for cancer patients. *Support Care Cancer*. 2022; 30: 8705-8731. doi: <https://doi.org/10.1007/s00520-022-07178-0>.
29. Mohamed AOA, Babiker ABG, Abdalla AEA, et al. Studying the accessibility of healthcare services for cancer patients in Khartoum state amid the COVID-19 pandemic. *Public Health Pract (Oxf)*. 2024; 7: 100497. doi: <https://doi.org/10.1016/j.puhip.2024.100497>.
30. Brasil 2020 BRASIL. Secretaria Geral da Presidência da República. Lei nº 14.023, de 8 de julho de 2020. Available <http://www.planalto.gov.br/ccivil_03/_ato2019-2022/2020/lei/L14023.htm#art1>.