

# Urethral Obstruction Secondary to Hyperplasia of Seminal Vesicle Glands in an Intact Male African Pygmy Hedgehog (*Atelerix albiventris*)

## Key words

accessory sex glands;  
small mammals;  
reproductive tract

**Lucia Kasalova<sup>1\*</sup>, Hana Černočová<sup>1</sup>, Radka Dvořáková<sup>2</sup>, Aneta Angelová<sup>3</sup>, Zdeněk Knotek<sup>1</sup>**

<sup>1</sup>Avian and Exotic Animal Clinic, Faculty of Veterinary Medicine, University of Veterinary Sciences Brno, Palackého tř. 1946/1, 612 42, Brno, <sup>2</sup>Department of Imaging Methods, Faculty of Veterinary Medicine, Dog and Cat Clinic, University of Veterinary Sciences Brno, Palackého tř. 1946/1, 612 42, Brno, <sup>3</sup>Department of Pathological Morphology and Parasitology, Faculty of Veterinary Medicine, University of Veterinary Sciences Brno, Palackého tř. 1946/1, 612 42, Brno, Czech Republic

\*Corresponding author: kasaloval@vfu.cz

**Abstract:** A 4-year-old, male, intact African pygmy hedgehog was presented at the clinic with a 2-day history of weakness. Clinical examination revealed a large fluid-like mass, suspected to be the urinary bladder. The surveying ultrasound confirmed an enlarged urinary bladder with anechoic content and a small amount of floating echoic material. The patient was not able to urinate nor was it possible to place an urinary catheter. After three days he continued to be non-responding to any medical approach. The patient was prepared for explorative surgery, during which he collapsed and was declared deceased. The following autopsy revealed an extramural urethral obstruction caused by the enlarged seminal vesicle glands. The histology examination confirmed hyperplasia of the glandular epithelial cells, with focal squamous metaplasia. A focal mild perivascular inflammatory infiltrate was also present, formed mainly by lymphocytes and plasma cells with isolated macrophages and admixtures of eosinophilic granulocytes.

Received: 3 September 2024

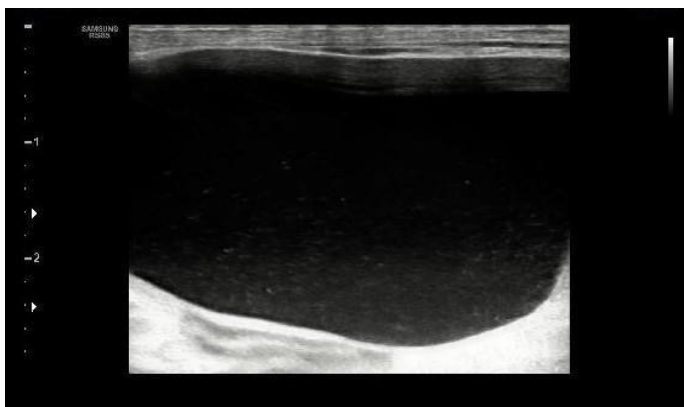
Accepted: 14 May 2025

## Introduction

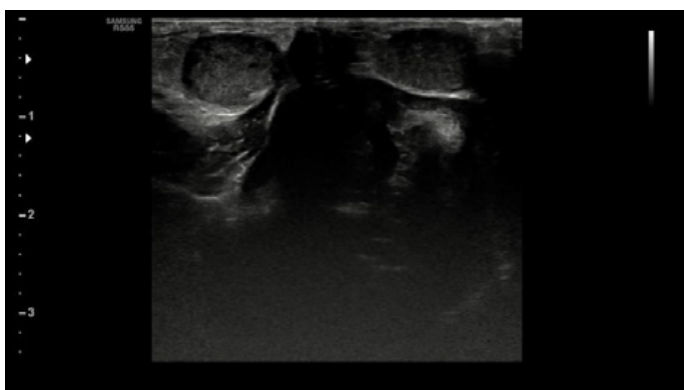
A 4-year-old, male, intact African pygmy hedgehog was presented at the clinic with a 2-day history of weakness of hind legs, lethargy, and visible abdominal distension. Clinical examination revealed a body conditional score of 2/5 with the weight being 420g, ongoing periodontitis, and a massive *Caparinia tripilis* infestation. Palpation of the abdomen was limited due to a fluid-like mass, suspected to be the urinary bladder. The owner could not state whether the animal was urinating and defecating normally. The patient was kept as a solitary pet in an aquarium with paper bedding. He was adopted from his previous owners at 2 years old. The current owner was not able to change his dietary preference, therefore he was eating mostly mealworms and occasionally kibble for kittens.

## Case presentation

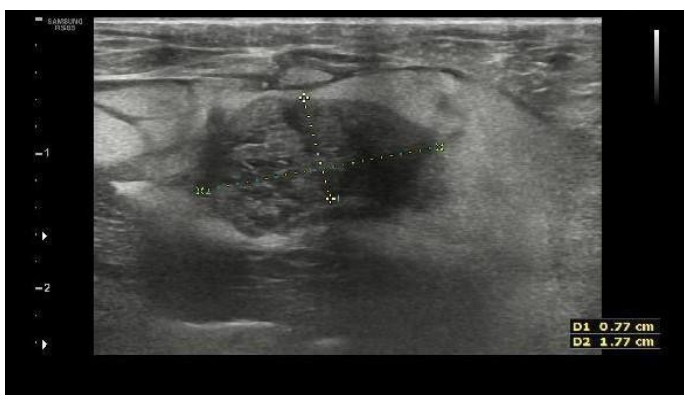
Surveying ultrasound (linear probe LA4 – 18B, frequency 4 – 18 MHz, Samsung RS85 prestige, Samsung Medison Co., Ltd., Seoul, South Korea) was performed under inhalation anaesthesia using a 3 % isoflurane (Aerrane 100% 250 ml, Baxter S. A. Bd., Belgium) concentration with a 2 l/min O<sub>2</sub> flow. The ultrasound confirmed an enlarged urinary bladder with anechoic content and a small amount of floating echoic material (Fig. 1). The bladder wall was not thickened. Cystocentesis was not performed due to the risk of rupture of the urinary bladder. It was possible to examine other organs like testicles (Fig. 2) and a part of the accessory sex glands (Fig. 3) with a visible heteroechoic structure (sized 0,77 x 1,77 cm). It was not possible to visualize a large part of the abdominal cavity. This was due to the overexpanded urinary bladder.



**Figure 1:** Ultrasonography of the abdominal cavity of the male African pygmy hedgehog. Distended urinary bladder with anechoic fluid and a small amount of echoic material, gravity-dependent



**Figure 2:** Ultrasonography of the African pygmy hedgehog. Visualization of both testicles (1) inside of the abdominal cavity and penis (2)



**Figure 3:** Ultrasonography of the abdominal cavity of the male African pygmy hedgehog. Enlarged seminal vesicle glands with hyperechoic surrounding fat and a small amount of free fluid

The blood collection was performed from *v. cava cranialis* later that day, under inhalation anaesthesia using a 3 % isoflurane concentration with a 2 l/min O<sub>2</sub> flow. Biochemistry of the plasma revealed elevated urea, with normal creatinine levels, and altered liver enzymes (elevated ALT and ALP) (Tab. 1). Haematological examination revealed mild leukocytosis with eosinophilia and monocytosis (Tab. 2). Remaining values were within normal range.

**Table 1:** Plasma biochemistry profile of the male African pygmy hedgehog

| Parameters | SI units | Value | RI <sup>1</sup> |
|------------|----------|-------|-----------------|
| Protein    | g/l      | 65.6  | 58 ± 7          |
| Albumin    | g/l      | 29.1  | 29 ± 4          |
| Bilirubin  | µmol/l   | <0.9  | 5.13 ± 5.13     |
| Creatine   | µmol/l   | 31.8  | 35.37 ± 17.68   |
| Urea       | mmol/l   | 23.2  | 10.68 ± 3.21    |
| Glucose    | mmol/l   | 5.6   | 4.94 ± 1.67     |
| ALP        | µkat/l   | 1.35  | 0.85 ± 0.35     |
| ALT        | µkat/l   | 2.50  | 0.88 ± 0.4      |
| AST        | µkat/l   | 0.96  | 0.56 ± 0.37     |

**Table 2:** Haematology of the male African pygmy hedgehog

| Parameters   | SI units            | Value | RI <sup>1</sup> |
|--------------|---------------------|-------|-----------------|
| Haemoglobin  | g/l                 | 122   | 120 ± 28        |
| Haematocrit  | %                   | 40.5  | 36 ± 7          |
| Erythrocytes | 10 <sup>12</sup> /l | 6.0   | 6 ± 2           |
| Leukocytes   | 10 <sup>9</sup> /l  | 17.9  | 11 ± 6          |
| Thrombocytes | 10 <sup>9</sup> /l  | 109   | 226 ± 108       |
| Lymphocytes  | 10 <sup>9</sup> /l  | 5.12  | 4.0 ± 2.2       |
| Monocyte     | 10 <sup>9</sup> /l  | 1.16  | 0.3 ± 0.3       |
| Neutrophils  | 10 <sup>9</sup> /l  | 6.85  | 5.1 ± 5.2       |
| Basophils    | 10 <sup>9</sup> /l  | 0.21  | 0.4 ± 0.3       |
| Eosinophils  | 10 <sup>9</sup> /l  | 4.63  | 1.2 ± 0.9       |

The owners were offered the option of an explorative laparotomy, however, they decided on conservative therapy. The patient was therefore admitted for stabilization and further observation.

Supportive care included subcutaneous administration of fluids with amino acids and vitamins – Hartmann solution (B Braun, Germany) + Duphalyte (Zoetis, Spain) in the ratio of 5:1 (4 ml pro toto SC, q12h).

Analgesia consisted of meloxicam (0.2 mg/kg SC, q12h; Melovem 5 mg/ml; Dopharma research B. B., Netherlands).

Other medications included an antiemetic drug maropitant (1 mg/kg SC, q24h; Cerenia 10 mg/ml; Zoetis Belgium SA, Belgium), and H2 blockers famotidine (0.4 mg/kg IM, q12h; Quamatel 20 mg/5 ml; Gedeon Richter Plc. Hungary). To relieve the spasm of the urinary bladder the patient received butylscopolaminium-bromid (10 mg/kg IM, q12h; Buscopan 20 mg/ml; IPSEN Consumer HealthCare, France). As for antibiotic therapy, due to leukocytosis, the patient received amoxicillin-clavulanate (25 mg/kg PO, q12h; Noroclav 50 mg/tbl; Norbrook, Ireland) in his meal, which was shortly eaten. At one time, when the patient refused to eat, the antibiotics were administered directly *per os* with a syringe.

On the third day of hospitalization, less than 48 hours after admission and the start of conservative treatment, there were no changes in the abdominal distension, nor was the patient able to urinate. The following attempt to place an urinary catheter to release some pressure was unsuccessful. The case was consulted with the owners who this time agreed to perform an explorative laparotomy, due to the high risk of rupture of the urinary bladder and kidney damage.

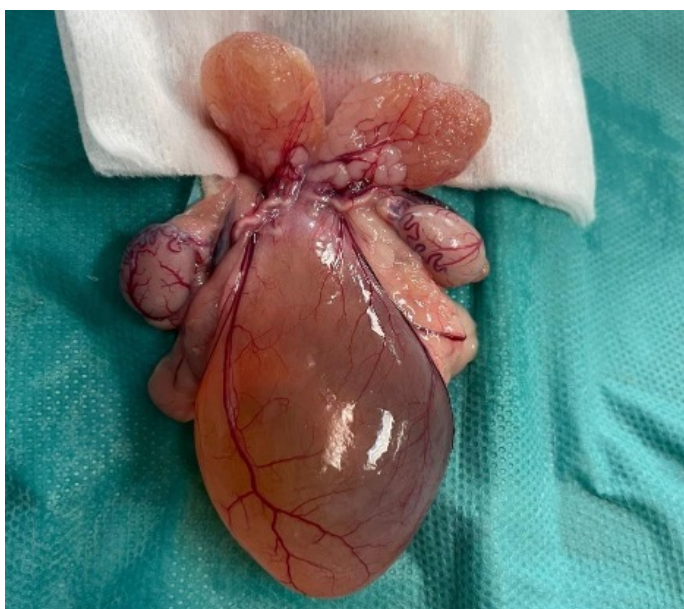
The patient was prepared for anaesthesia according to the standard protocol used at the clinic: premedication consisted of medetomidine (0.02 mg IM pro toto; Cepetor 1 mg/ml; CP – Pharma Handelfsges. mbH, Germany), ketamine (1 mg IM pro toto; Narkamon 50 mg/ml; Bioveta a.s., Czech Republic) and midazolam (0.05 mg IM pro toto; Midazolam Accord 5 mg/ml; Accord Healthcare Limited, Great Britain). Anaesthesia was induced with a mask using a 5% concentration of isoflurane and an oxygen flow at the rate of 2 O2l/min. After induction, the concentration was lowered to 2.5 % of isoflurane. The patient received an IV

catheter to the cephalic vein. After the sterile surgical field was prepared, the patient collapsed. The anaesthesia was turned off, maintaining the patient on a high O2 flow at 4l/min. Cardiac massage via chest compressions was performed to maintain blood flow at the highest possible rate, approximately 120 – 150 beats per minute. The breathing was secured by mouth-to-mouth-to-nose breathing as it wasn't possible to perform the intubation. As neither of these attempts was successful a bolus of epinephrine (0.1 mg/kg IV; Adrenalin Léčiva 1 mg/ml; Zentiva, k.s., Czech Republic) diluted in 1 ml of Hartmann solution was administered directly in the IV catheter. The resuscitation was unsuccessful and the patient was declared deceased.

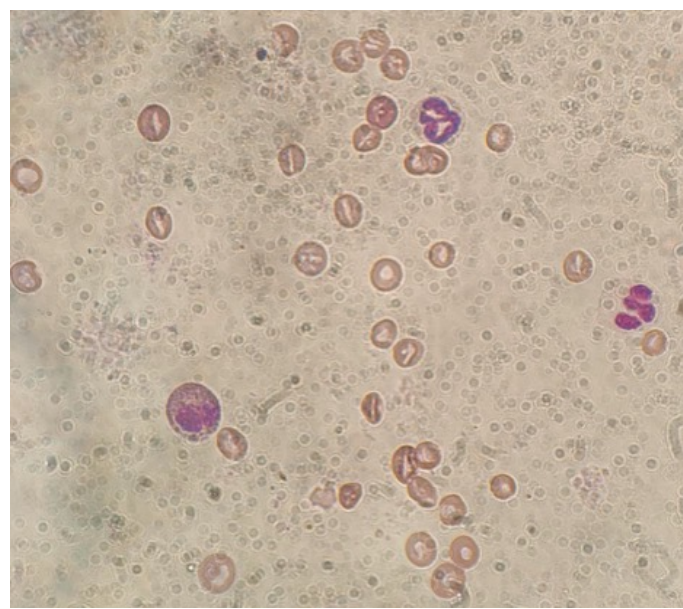
The autopsy revealed an enlarged urinary bladder as a result of an extramural urethral obstruction (Fig. 4). This obstruction was caused by applied pressure and partial strangulation from one of the enlarged vesicular seminal glands. A cytology impression smear and a sample for microbiological and histological examination were obtained from one of these glands.

Cytology showed the presence of multiple leucocytes, with neutrophils, eosinophils, and monocytes equally present together with clusters of cuboidal epithelial cells, with granular basophilic cytoplasm and an oval nucleus located at the base of the cells (Fig. 5). Cultivation of the samples presented two colonies of bacteria: *Staphylococcus simulans* and *Enterococcus faecalis*.

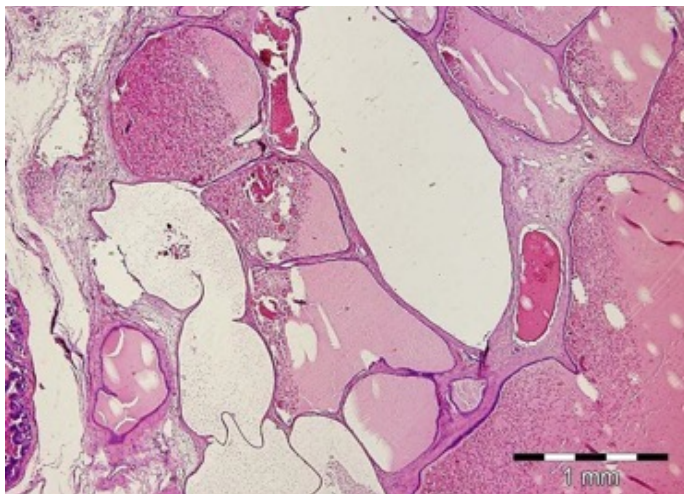
In the obtained biopsy of the altered gland, a mild chronic interstitial inflammation with cystic dilatation of acini and ducts of the gland was observed. The cells of the



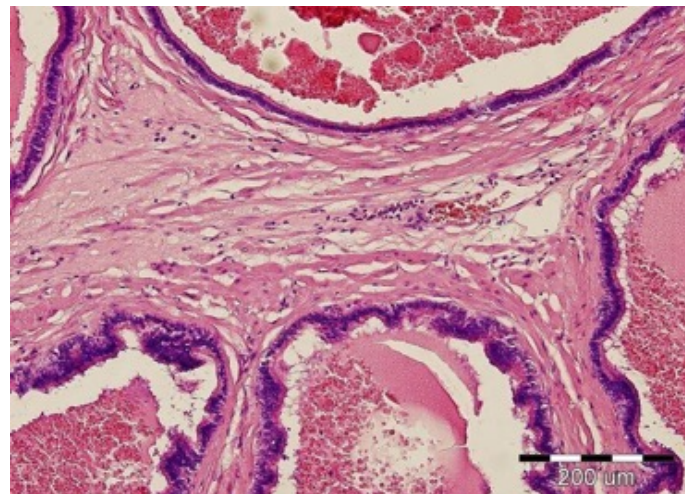
**Figure 4:** Obstructed and distended urinary bladder (1). Visualization of the reproductive tract: testicles (2), enlarged seminal vesicle glands (3) obstructing the urethra



**Figure 5:** Impression smear from the enlarged seminal vesicle glands. Cytology revealed erythrocytes (1) and leucocytes, with a different number of neutrophils (2), eosinophils (3), monocytes, and lymphocytes



**Figure 6:** Histology examination from the biopsy of seminal vesicle gland of African pygmy hedgehogs. Hyperplasia of the glands with cystic structures. Dilatation of acines with a small amount of condensed secret. HE, magnification 40x



**Figure 7:** Histological examination from the biopsy of seminal vesicle gland of African pygmy hedgehog. In the interstitial connective tissue of the seminal vesicles, focally mild perivascular inflammatory infiltrate consisting mainly of lymphocytes and plasma cells with isolated macrophages and admixture of eosinophilic granulocytes. Focal oedema of the interstitium and mild fibrosis, hyperemia of blood vessels, and isolated hemorrhages. HE, magnification 200x

glandular epithelium presented signs of hyperplasia with focal squamous metaplasia. A focal mild perivascular inflammatory infiltrate was also present, formed mainly by lymphocytes and plasma cells with isolated macrophages and admixtures of eosinophilic granulocytes (Fig. 6, Fig. 7).

## Discussion

To date, there is limited information available about the reproductive tract of the African pygmy hedgehog, especially the males.

The presented case was a male, older than 4 years of age. African pygmy hedgehogs are considered reproductively old from 2 – 2.5 years old, with their life span being 4 – 6 years old (1, 2). Pathologies of the reproductive tract in intact individuals (both males and females) are a common problem in geriatric patients. The majority of cases are described in females, with the most common one being a neoplasia of the uterus (3,4).

A recent study has focused on the ultrasonographic description of both male and female reproductive systems, however, the gross anatomy of the seminal vesicle glands was not described (5). A retrospective study mentioned hyperplasia of seminal vesicles in an intact male, without any further detailed description (6). Another recent study describes the first case of hyperplasia of the seminal vesicles that obstructed the gastrointestinal system (7).

The authors of the article mentioned that seminal vesicle glands in African pygmy hedgehogs may behave similarly to the prostate of intact dogs (7). Benign prostatic hyperplasia is a common disease documented

mainly in old non-sterilised canine males. This condition develops as the exposure of the prostate to the hormone dihydrotestosterone (8). Untreated prostatic hyperplasia may develop into a prostatic abscess, which can cause further complications (8).

There is a discussion about whether a similar process can occur in other small mammals as well, such as African pygmy hedgehogs (7). A recent study described a case of vesicular gland infection and prostatitis in an intact Guinea pig (9). The patient was presented with ongoing anuria and lethargy. After not succeeding with conservative treatment the patient was admitted for surgery. This consisted of abdominal castration and extirpation of the vesicular glands, as well as cleaning multiple prostate abscesses (9). A similar surgical approach could be considered in the case of inflammation and hyperplasia of the seminal vesicle glands in African pygmy hedgehogs, where castration would be also recommended.

In this case, the infection could be a result of either an ascended infection from the urinary bladder or a haematogenous infection from a different primary source. An infection of the accessory sex glands may occur if the patient is suffering from untreated cystitis. In this presented case the cultivation showed the presence of *Staphylococcus simulans* and *Enterococcus faecalis*. A retrospective study on Guinea pigs showed that 55.5 % of presented cases were diagnosed with bacterial cystitis and/or other UTIs (10). Cultivation from this study confirmed the presence of more than one bacterial species, presenting *Pseudomonas* spp., *Staphylococcus* spp., and *Escherichia coli* (10).

## Conclusion

---

This case study supports the theory that more attention should be given to preventive sterilization of the males. Hyperplasia of seminal vesicle glands in African pygmy hedgehogs might be more frequent than previously thought, similar to prostate hyperplasia in dogs. However, due to their behaviour and problematic handling, male hedgehogs might show less noticeable symptoms than dogs. If specific signs are seen, then the disease associated with accessory sex glands is usually more advanced with further complications. Therefore castration of African pygmy hedgehog males should be offered to owners as a way to prevent possible complications such as obstruction of different organs inside of the abdominal cavity.

## References

---

1. Ivey E, Carpenter JW. African pygmyhedgehogs. In: Quesenberry EK, Carpenter JW, eds. *Ferrets, Rabbits, and Rodents*. 3rd ed. St. Louis: Elsevier, 2011: 417.
2. Brodie, ED, Brodie ED JR, Johnson AJ. Breeding the African hedgehog in captivity. *Int Zoo Yearbook* 1982; 22(1): 195–7.
3. Mikaelian I, Reavill DR, Practice A. Spontaneous proliferative lesions, and tumors of the uterus of captive African hedgehogs (*Atelerix albiventris*). *J Zoo Wildl Med* 2004; 35(2): 216–20. doi: 10.1638/01-077
4. Chambers JK, Shiga T, Takimoto H, et al. Proliferative lesions of the endometrium of 50 four-toed hedgehogs (*Atelerix albiventris*). *Vet Pathol* 2018; 55(4): 562–71. doi: 10.1177/0300985818758467
5. Astudillo-Gajardo M, Morales-Muñoz P, Sáez-Vidales D. Caracterización ecográfica del sistema reproductor de machos y hembras de erizo de tierra Africano (*Atelerix albiventris*). *Rev Cient Fac Cienc Vet Univ Zulia* 2017; 27(5): 328–35.
6. Okada K, Kondo H, Sumi A, Kagawa Y. A retrospective study of disease incidence in African pygmy hedgehogs (*Atelerix albiventris*). *J Vet Med Sci* 2018; 80(10): 1504–10. doi: 10.1292/jvms.18-0238
7. Wooten M, Snider TA. Gastrointestinal obstruction secondary to seminal vesicle cystic hyperplasia in an African pygmy hedgehog (*Atelerix albiventris*). *Vet Rec Case Rep* 2022; 10(4): e446. doi: 10.1002/vrc2.446
8. Davidson AP. Reproductive system disorders. In: Nelson RW, Couto CG, eds. *Small animal Internal medicine*. 6th ed. St. Louis: Elsevier; 2020: 1001–3.
9. Picazo L, Del Romero A, Rosell J, Aguilo-Gisbert J. Vesicular gland infection caused by *Pseudomonas aeruginosa* with secondary prostatitis in a guinea pig (*Cavia porcellus*). *J Exot Pet Med* 2024; 48: 20–4. doi: 10.1053/j.jepm.2024.01.002
10. Azevedo S, O'Malley B, Greene C, Moran H, Magalhães TR, Queiroga FL. Lower urinary tract diseases in Guinea pigs: a 14-year retrospective study (2004–2018). *Animals (Basel)* 2022; 13(1): 112. doi: 10.3390/ani13010112

---

## **Obstrukcija sečnice zaradi hiperplazije mehurnice pri nekastriranem samcu afriškega beloprsega ježa (*Atelerix albiventris*)**

L. Kasalova, H. Černočová, R. Dvořáková, A. Angelová, Z. Knotek

**Izveček:** Štiriletnega nekastriranega samca afriškega beloprsega ježa so pripeljali na kliniko zaradi znakov oslabelosti, ki so trajali dva dni. Klinični pregled je pokazal veliko tekočini podobno maso, za katero se je domnevalo, da gre za sečni mehur. Ultrazvočni pregled je potrdil povečan sečni mehur z anehogeno vsebino in majhno količino plavajočega ehogenega materiala. Jež ni mogel urinirati, prav tako ni bilo mogoče namestiti urinskega katetra. Po treh dneh se še naprej ni odzival na noben način zdravljenja. Izveden je bil eksplorativni kirurški poseg, med katerim je poginil. Pri obdukciji je bila ugotovljena ektramuralna obstrukcija sečnice, ki jo je povzročila povečana mehurnica. Histološka preiskava je potrdila hiperplazijo žleznih epitelijskih celic z žariščno skvamozno metaplazijo. Prisoten je bil tudi blag žariščni perivaskularni vnetni infiltrat, ki so ga sestavljali pretežno limfociti in plazmatke s posameznimi makrofagi ter primesmi eozinofilnih granulocitov.

**Ključne besede:** pomožne spolne žleze; mali sesalci; reproduktivni trakt