

THE AMELIORATIVE EFFECT OF *ALKANNA ORIENTALIS* EXTRACT AGAINST *CERASTES CERASTES* VENOM HEPATIC AND HEMATOLOGICAL TOXICITY

Mahmoud M. Nasser^{1*}, Abd El-Aziz A. Diab², Soliman S.A. Ibrahim², Ahmed L. El-Said¹, Eman M.E. Mohallal¹, Samih I. El-Dahmy³

¹Desert Research Center, Cairo, 11753, ²Zoology Department, Faculty of Science, Zagazig University, 44519, ³Pharmacognosy Department, Faculty of Pharmacy, Zagazig University, 44519, Egypt

*Corresponding author: nasser_mahmoud55@yahoo.com

Abstract: *Cerastes cerastes* is the most abundant venomous snakes of the North Africa, envenoming by it inflicts local tissue damage, hemorrhage and causing severe systemic toxicity that usually lead to victim death. Therefore, the present study aimed to evaluate the toxicity of *Cerastes cerastes* venom on male albino rats and the ameliorative and prophylaxis role of *Alkanna orientalis* extract against venom toxicity. Forty-eight adult male albino rats (180±200g) were divided into 6 groups. Group I injected intraperitoneal with physiological saline (100µl). Group II with *Alkanna orientalis* extract (250mg/kg/BW). Group III was injected with 1/10 LD₅₀ of *Cerastes cerastes* venom (0.435mg/kg/BW). Group IV injected with *Cerastes Cerastes* venom (0.435mg/kg/BW) then immediately with *Alkanna orientalis* extract. Group V was given *Alkanna orientalis* extract orally (250mg/kg/b.wt) then after 2 hours injected with *Cerastes cerastes* venom (0.435 mg/kg/BW) Group VI was injected with *Cerastes cerastes* venom then was injected immediately with antivenom immunoglobulin (300µl). Group III showed a significant increase ($p<0.001$) in serum aspartate transaminase, alanine transaminase, alkaline phosphatase and total &direct bilirubin as well as a significant decrease($p<0.001$) in plasma prothrombin and partial thromboplastin concentration, plasma albumin, total protein, serum cholinesterase, hemoglobin, red blood cells and platelets count as compared with control group. In addition, it resulted in internal abdominal cavity hemorrhage. While, group II did not show any significant change in all previous parameters. As well as, *Alkanna orientalis* extract when given intraperitoneal immediately or orally 2 hours before *Cerastes cerastes* venom as antidote, it minimize the alterations of hematological, biochemical parameters and the internal hemorrhage. By comparing groups IV and V with group VI, we found out that *Alkanna orientalis* extract could be considered more effective antidote than antivenom immunoglobulin for *Cerastes cerastes* venom toxicity. In conclusion, *Alkanna orientalis* extract showed a new therapeutic and prophylaxis agents against *Cerastes cerastes* venom toxicity.

Key words: *Cerastes cerastes*; *Alkanna orientalis*; *Boraginaceae* family; venom toxicity; haematological effect

Introduction

Snake's envenomation has been reported as an important social and medical serious problems in the snakes natural habitat, up to 1.8–2.5 million victims occurred per a year with about 100,000–125,000 mortality occurred annually and more than 100,000 of victims are suffering from severe complications, which can lead to amputation of the attacked part (1). In Egypt, 1000–10,000 incidences of snake's envenomation per year with about 11–100 death cases annually (2). *Cerastes cerastes* (the Egyptian desert horned viper) showed a widely distribution also, it can be considered as the most dangerous vipers of the Middle East and North Africa (3).

Cerastes cerastes vipers envenoming was documented to cause prominent local tissue damage, that results in the disruption of the extra cellular matrix and the basement membrane covering the body vessels and blood capillaries which responsible for rapid discharge of target-specific toxins (4). Kebir-Chelghoum and Laraba-Djebari (5) reported that the venom able to induce cell toxicity that change the membrane permeability resulting in discharging of the internal cell contents, oxidative stress as well as, it cause an indirect inflammatory response. Therefore, the usage of anti-inflammatory and antioxidant drugs may be important in the treatment of bitten victims. In addition, cerebrovascular complications and neuromuscular paralysis previously documented as a neurological toxic effect of snakebites (6).

Although the antivenom can neutralize the venom and prevent further damage it cannot restore the damage that was already occurred (7). Therefore, it is very important to find out new natural or artificial venom inhibitors, which able to complement the antivenom action especially, in restoring the local tissue damage (8). Proteins, antioxidants, glycosaminoglycans, polysaccharides, flavonoids and alkaloids considered as venom spreading factors inhibitors (9). The usage of medicinal plants was the policy of the World Health Organization (WHO) since 1970. Plants and herbs considered as pharmacological ingredient sources that provide about 25% of drugs that recently used (10). Because of the

low cost of traditional medicinal plants, it is widely used for diseases treatment in countries with low-income populations (11).

Boraginaceae family consists of several shrub plants which abundant in mild and tropical regions. It is classified into 200 genus and 2000 species, most of these plants have important medicinal effects. Flowers, stems, roots and leaves of them are used for medicinal purposes (12). *Boraginaceae* was reported as an antidote for some snakebite such as, *Argusia Argentea* methanolic extract is effective in *Trimeresurus Flavoviridis* bites (13). *Carmona retusa*, whole of the plant was used as antidote paste for *Daboia russelii* bites (14). Rosmarinic acid from methanolic extract of *cordial verbenacea* is effective against *B. Jararacussu* (15).

Boraginaceae, especially *Alkanna orientalis* and *Echium humil*, contain valuable amounts of gamma-linolenic acid (GLA), alpha-linolenic acid (ALA) and stearidonic acid (SDA) in addition to rosmarinic acid (RA). These substances have a potent antioxidant and anti-inflammatory effect thus; they can restore the toxic effect of *Cerastes cerastes* venom (16–18).

Alkanna orientalis (*Boraginaceae*) is considered a rich source of RA that acts as antioxidant, anti inflammatory, anti mutagen, antibacterial, and antiviral activities (19). The inhibitory activity of RA against snake venom phospholipases A2 from *Cordia verbenacea*. as well as, the interaction between RA and phospholipases A2, by using crude venoms and purified phospholipases A2 of *B. jararaca* was reported by Ticli et al. (20). The hemorrhagic snake venoms are known to be metalloproteinases, and their mechanism of action would be different from that of phospholipases A2. Accordingly, it is interesting that RA inhibits both metalloproteinase and phospholipases A2 (20). On the same pattern, El Sohly et al. (21) documented the first report on flavonols from aerial parts of *Alkanna orientalis*. Flavanoids are one of the foremost plant components that work against PLA₂ and lipooxygenase, they possess anti inflammatory, anti hepatotoxic, anti allergic, antitumor and enzyme inhibiting properties. Flavanoid weakly inhibits the group I PLA₂ from *Naja naja* and strongly inhibits the

group II PLA2 from *Vipera* (22). Hence, this study was designed to clarify the ameliorative impact of *Alkanna orientalis* extract in comparison with antivenom immunoglobulin against *Cerastes cerastes* toxicity.

Material and methods

Experimental animals

Male albino rats (n=88), weighing 180–200 gm, were obtained from the Animal house, Faculty of Science, Zagazig University. The animals settled in plastic cages, fed a standard diet and water. Exposed to a 12 h light/dark cycle, and maintained at a laboratory temperature of 22±2°C. The rats quarantined for 15 days before the experiments. All Institutional and National Guidelines for the care and use of animals were followed.

Cerastes cerastes venom

Twenty-five *Cerastes cerastes* vipers collected from New Valley (El Kharga), settled in plastic cages at physiology lab in the desert research centre. They were milked by allowing these vipers to inject its venom through a rubber into a small beaker, and then the venom was rapidly frozen in liquid nitrogen until it was used in the study.

Cerastes cerastes venom LD₅₀

LD₅₀ of *Cerastes cerastes* venom was determined according to the method described by Ramakrishnan (23). A total of 40 adult male albino rats were divided into 5 groups (gp I-V), injected intraperitoneal (i.p.) with *Cerastes cerastes* venom at dose of 2.0, 3.0, 4.0, 5.0, 6.0 mg/kg/BW for each group, respectively. Dead and alive rats in each group 24 hours post injection were recorded. The calculated LD₅₀ was 4.35 mg / kg/BW according to $\text{Log LD}_{50} = \log \text{LD next below } 50\% + \log \text{ increasing factor } X \text{ proportionate distance}$. The proportionate distance = $[(\text{mortality at dilution next above } 50\%) - 50\%] / [(\text{mortality next above } 50\%) - (\text{mortality next below } 50\%)]$.

Alkanna Orientalis extraction

Alkanna Orientalis extract was prepared according to Sukhdev et al. (24) method for

intraperitoneal administration. *Alkanna Orientalis* plant obtained from Saint Katherine, South Sinai, Egypt, where it grow, and then it was left in air for drying without direct sun heat. After drying, the plant was grinded then immersed in 70% ethyl alcohol for 4 days. The extract filtered and concentrated at room temperature. The dried extract was stored at 4°C until using.

Antivenom

Antivenom immunoglobulin was obtained from VACSERA CO., Agouza .Giza, Egypt.

Animal treatment schedule

The period of this study is 2 hours after *Cerastes cerastes* venom injection, as acute dose and in group II rats were sacrificed after 2 hours of *Alkanna orientalis* extract injection.

A total of 48 Male albino rats were divided into six groups (n=8/group), as the following:

Group I (control group): rats were injected (i.p.) with 100µl of 0.09% physiological saline
Group II (*Alkanna orientalis* treated group): rats were injected (i.p.) with *Alkanna orientalis* extract (250 mg/kg/BW) dissolved in 100µl distilled water.
Group III (*Cerastes cerastes* venom treated group): rats injected (i.p.) with *Cerastes cerastes* venom (0.435 mg/kg BW) that represent 1/10 LD₅₀, dissolved in 100µl of 0.09% physiological saline.
Group IV (*Cerastes cerastes* venom + *Alkanna orientalis* extract) group: rats injected (i.p.) with 1/10 LD₅₀ *Cerastes cerastes* venom (0.435mg/kg/BW) dissolved in 100µl of 0.09% physiological saline then, immediately injected (i.p.) with *Alkanna orientalis* extract (250 mg/kg/BW) dissolved in 100 µl distilled water.
Group V (a prophylaxis group): rats were given *Alkanna orientalis* extract orally (250 mg/kg/BW) then after 2 hours were injected (i.p.) with 1/10 LD₅₀ *Cerastes cerastes* venom (0.435 mg/kg BW) dissolved in 100µl of 0.09% physiological saline.
Group VI (*Cerastes cerastes* venom + antivenom): rats were injected (i.p.) with 1/10LD₅₀ of *Cerastes cerastes* venom (0.435 mg / kg/BW) dissolved in 100 µl of 0.09 % physiological saline, then were immediately injected (i.p.) with 300 µl of antivenom immunoglobulin.

Blood sampling

Rats of each group were sacrificed after 2 hours of *Cerastes cerastes* venom injection and blood samples were collected in three sterile tubes, two containing anticoagulant (sodium citrate and EDTA) and one without anticoagulant. The serum separated from clotted blood and used for the determination of biochemical parameters, while, citrate and EDTA tubes were used for determination of plasma prothrombin/partial thromboplastin concentration and blood component respectively.

Evaluation of some biochemical and hematological parameters

Biochemical parameters carried out by spectrophotometric (BT-260) analysis. Estimation of Aspartate and alanin transaminase (ALT and AST) was performed according to Reitman and Frankel (25). Alkaline phosphatase (ALP) (26) and total protein and albumin were detected (27). Total and direct bilirubin, serum cholinesterase and plasma prothrombin concentration (PT) & plasma partial thromboplastin concentration (PTT) were measured as previously measured (28-30). Hemoglobin concentration (Hb) as well as, determination of red blood cells (RBCs), white blood cells (WBCs) and platelets count were performed (31, 32).

Evaluation of internal hemorrhage in rat's abdominal cavity

Rats in each group were sacrificed after 2 hours of *Cerastes cerastes* venom injection then, the rats' abdominal cavities were examined for internal hemorrhage.

Statistical analysis

The obtained data were analyzed by the statistical analysis software (SAS-2013 prog-

ram), for obtaining Mean values \pm standard error. Subsequent multiple comparisons between the different groups were analyzed by Duncan's multiple comparison tests (33), values at ($P < 0.05$) were considered significant (34).

Results

Liver function parameters and cholinesterase

Table (1) depicting the effect of *Cerastes cerastes* venom and the ameliorative role of *Alkanna orientalis* extract and antivenom on some liver function parameters and cholinesterase in the different groups. Rats that injected with *Cerastes cerastes* venom (group III), showed a significant increase ($P < 0.001$) in serum level of ALT, AST, ALP, total and direct bilirubin, and a significant decrease ($P < 0.001$) in serum albumin, total protein and serum cholinesterase as compared with control group (group I). While, *Alkanna orientalis* extract (group II) showed a non-significant effect in all previous parameters after 2 h from injection of it, as compared with control group.

Whereas, when *Alkanna orientalis* was injected (i.p.) immediately after *Cerastes cerastes* venom or given orally 2 hours before *Cerastes cerastes* venom as a prophylaxis dose, (groups IV and V, respectively), it was able to ameliorate the hepatotoxic effect of the venom. As it showed a significant decrease ($P < 0.001$) in ALT, AST, ALP, total & direct bilirubin and a significant increase ($P < 0.001$) in serum albumin, total protein and cholinesterase as compared with venom treated group. On the same pattern, antivenom immunoglobulin showed a significant ameliorative effect against the venom when given (i.p.) immediately after *Cerastes cerastes* crude venom injection.

Table 1: Effect of *Cerastes cerastes* venom, *Alkanna orientalis*, antivenom and their combination on some liver function parameters in male albino rats

Parameter	Groups						P value
	Group I control	Group II AO	Group III Cc	Group IV Cc + AO	Group V AO + Cc	Group VI Cc + Anti	
ALT (U/l)	12.87±0.55 ^e	12.87±0.55 ^e	40.5±0.55 ^a	24.62±0.55 ^{cd}	23.57±0.55 ^d	31.62±0.55 ^b	< 0.001
AST (U/l)	15.12±0.77 ^e	14.87±0.77 ^e	44.5±0.77 ^a	29.37±0.77 ^c	24.65±0.77 ^d	34.87±0.77 ^b	< 0.001
ALP (U/l)	90.24±3.6 ^e	88.57±3.6 ^e	176.82±3.6 ^a	104.8±3.6 ^c	96.34±3.6 ^d	112.36±3.6 ^b	< 0.001
Total protein (g/dl)	6.26±0.05 ^a	6.21±0.05 ^a	4.88±0.05 ^d	5.85±0.05 ^b	5.9±0.05 ^b	5.51±0.05 ^c	< 0.001
Albumin (g/dl)	3.35±0.04 ^a	3.43±0.04 ^a	2.75±0.04 ^c	3.32±0.04 ^{ab}	3.39±0.04 ^a	3.23±0.04 ^b	< 0.001
Total bilirubin (mg/dl)	0.88±0.04 ^d	0.87±0.04 ^d	1.81±0.04 ^a	1.31±0.04 ^{bc}	1.23±0.04 ^c	1.41±0.04 ^b	< 0.001
Direct bilirubin (mg/dl)	0.3±0.02 ^{de}	0.26±0.02 ^e	0.59±0.02 ^a	0.36±0.02 ^{dc}	0.43±0.02 ^b	0.44±0.02 ^b	< 0.001
Cholinesterase (U/l)	3901±144 ^{ab}	4004±144 ^a	2145±144 ^d	3545±144 ^b	3568±144 ^b	2592±144 ^c	< 0.001

Indicated values were mean ± SE. Means within the same row in each category carrying different letters were significant at $P \leq 0.05$. AO: *Alkanna orientalis* extract; Cc: *Cerastes cerastes*; venom and Anti: antivenom immunoglobulin.

Hematological parameters

Concerning to the effect of *Cerastes cerastes* venom and the ameliorative role of *Alkanna orientalis* extract and antivenom immunoglobulin on hematological parameters (Table 2) revealed that, group III showed a significant decrease in Hb level, RBCs count, platelets count, prothrombin concentration and partial thromboplastin concentration in comparison with group I. Meanwhile, a significant increase ($P < 0.001$) in WBCs count was observed. While, *Alkanna orientalis* extract (group II) showed a significant decrease in WBCs count and non significant effect in the other parameters after 2 hours from (i.p.) injection of it when compared with control group as shown in Table (2). As well as, in groups IV and V

Alkanna orientalis was able to ameliorate the hematological toxic effect of the venom. It showed a significant increase in Hb level, RBCs count, platelets count, prothrombin concentration and partial thromboplastin concentrations. In addition, it showed a significant decrease in WBCs count when compared with the venom treated animals (group III). On the same pattern, antivenom immunoglobulin showed a significant ameliorative effect against the venom when given (i.p.) immediately after *Cerastes cerastes* crude venom injection. It showed a significant increase in Hb level, RBCs count, platelets count, prothrombin concentration and partial thromboplastin concentrations. In addition, it showed a significant decrease in WBCs count when compared with venom treated group as shown in Table (2).

Table 2: Effect of *Cerastes cerastes* venom, *Alkanna orientalis*, antivenom and their combination on some hematological parameters in male albino rats

Parameter	Groups						P value
	Group I control	Group II AO	Group III Cc	Group IV Cc + AO	Group V AO + Cc	Group VI Cc + Anti	
RBCs × 10 ⁶ /mm ³	5.32±0.13 ^a	5.35±0.13 ^a	3.83±0.13 ^c	5.45±0.13 ^a	5.51±0.13 ^a	4.66±0.13 ^b	< 0.001
Hb (mg/dl)	14.03±0.16 ^a	13.98±0.16 ^a	9.92±0.16 ^c	14.07±0.16 ^a	14.03±0.16 ^a	13.03±0.16 ^b	< 0.001
Platelets × 10 ³ /mm ³	368.12±10 ^a	390±10 ^a	50.12±10 ^d	321.12±10 ^b	372.1±10 ^a	247.62±10 ^c	< 0.001
WBCS × 10 ³ /mm ³	10.5±0.19 ^c	9.55±0.19 ^d	14.57±0.19 ^a	7.48±0.19 ^f	7.26±0.19 ^f	8.47±0.19 ^e	< 0.001
PT (%)	99.62±1.24 ^a	99.87±1.24 ^a	27.62±1.24 ^e	87.5±1.24 ^b	88.12±1.24 ^b	47.0±1.24 ^d	< 0.001
PTT (Sec)	37.25±0.85 ^d	36.25±0.85 ^d	53.5±0.85 ^a	41.12±0.85 ^c	42.62±0.85 ^c	46.37±0.85 ^b	< 0.001

Indicated values were mean ± SE. Means within the same row in each category carrying different letters were significant at $P \leq 0.05$. AO: *Alkanna orientalis* extract; Cc: *Cerastes cerastes* venom; Anti: antivenom immunoglobulin, PT: prothrombin concentration and PTT: partial thromboplastin time.

Internal hemorrhage

Group I and II showed normal abdominal cavity with normal internal organs without any hemorrhage as shown in (Figure 1a and b). While severe internal hemorrhage was observed in group III (Figure 1c). Mild internal hemorrhage was noticed in groups IV and V (Figure 1d and e) and the abdominal cavity of group VI showed less internal hemorrhage than

group III (Figure 1f). The obtained results showed that *Alkanna orientalis* extract when given as antidote for *Cerastes cerastes* venom hepatic, cholinergic, hematological toxicity and the internal hemorrhage was more effective than the synthesized antibody (antivenom immunoglobulin) and these results clearly appeared by comparing the findings of groups IV and V with group VI.

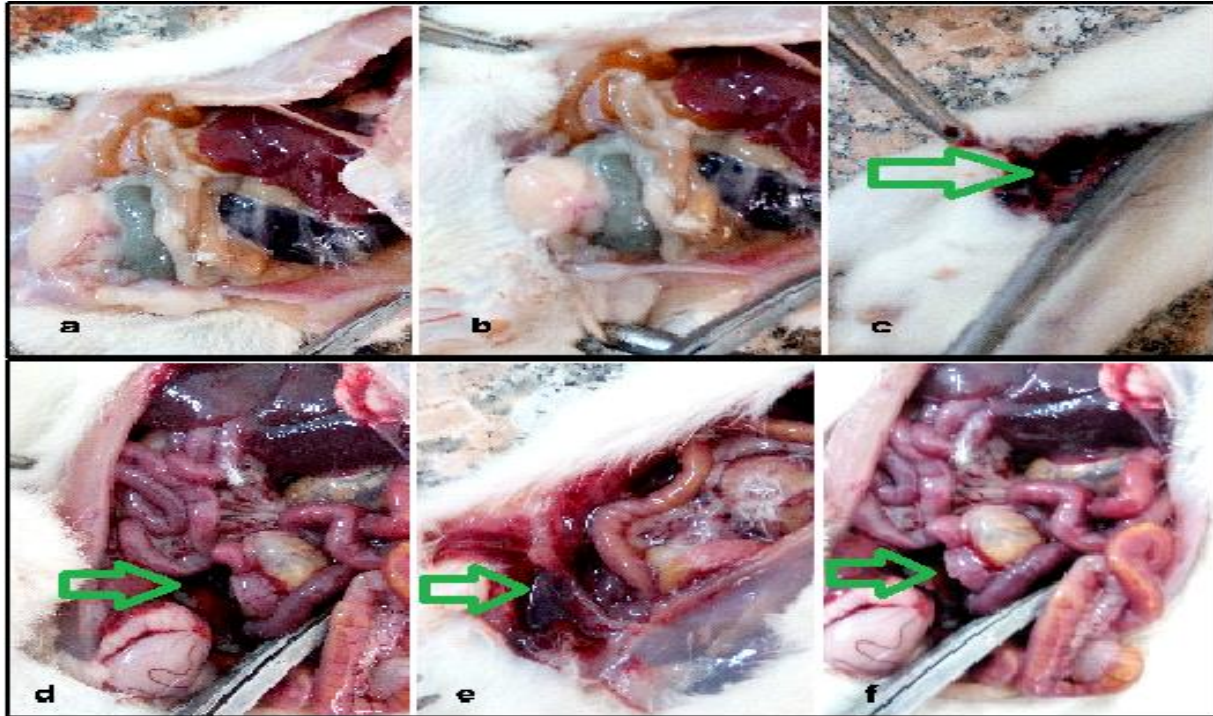


Figure 1: Illustrate the abdominal cavity of different groups in the study. (a) Showing the abdominal cavity of group I (control group) without hemorrhage, (b) showing the abdominal cavity of group II (*Alkanna orientalis* extract) without hemorrhage, (c) showing abdominal cavity of group III (*Cerastes cerastes* venom treated group) with sever internal hemorrhage as shown by the green arrow, (d) showing abdominal cavity of group IV (*Cerastes cerastes* venom + *Alkanna orientalis* extract) with less internal hemorrhage than group III as shown by the green arrow, (e) showing abdominal cavity of Group V (a prophylaxis group) with less internal hemorrhage than group III as shown by the green arrow and (f) showing abdominal cavity of group VI (*Cerastes cerastes* venom + antivenom) with less internal hemorrhage than group III as shown by the green arrow

Discussion

The intraperitoneal injection of *Cerastes cerastes* crude venom caused a reduction in serum total proteins and albumin in male albino rats. These findings were in agreement with Salman (35), who reported a significant reduction in serum albumin and total proteins in Guinea pigs injected with *Cerastes cerastes* crude venom after different hours. The main

factors that cause hypoproteinemia may be the disturbance in renal functions that result from the snake venom. As well as, the hemorrhage that commonly occurred with snakebites Also, the increase in vascular permeability due to the toxic effect of the crude venom can lead to the loss of protein in the tissues (36).

The current study showed a significant increase in serum total and direct bilirubin, ALT, AST and ALP enzymes after 2 hours of

Cerastes cerastes crude venom intraperitoneal injection in comparison to control group. These results go hand in hand with previous findings (35-37). ALT and AST enzymes considered a major markers for hepatocellular damage as ALT enzyme is essentially present in hepatocytes, these enzymes acts as monitoring for liver disease, inflammation and necrosis (38).

Measurement of the enzymes activities is important in assessment of vital organs, as the crude viper's venoms reported to affect the activities of several serum enzymes. These enzymes activities increased significantly after the liver damage, skeletal muscles and myocardial damage (39). In the present study, increasing in the activity of ALT, AST and ALP indicate the damage of liver and other organs by the venom. These results were in agreement with previous researches on the venoms of other snake species such as *Cerastes cerastes gasperetti*, *Echis carinatus*, *Walterinnesia aegyptia*, viper *B. arietans*, *Echis coloratusis*, *Naja haje* (40,41).

As well as, *Cerastes cerastes* venom according to the same program of treatment caused a significant decrease in serum cholinesterase. The decrease in serum cholinesterase level in rats following *Cerastes cerastes* venom injection is in agreement with Soares and Giglio (42). They reported that phospholipases A₂ constitute major components of *Cerastes cerastes* venom and it display a wide range of biological effects, including neurotoxic, myotoxic, cytotoxic. Also, Kini (43) reported that PLA₂ exhibit a presynaptic neurotoxicity. On the same pattern, a postsynaptic neurotoxin belonging to family *Viperidae* was isolated from the Egyptian sand viper *Cerastes cerastes* (44). These Postsynaptic neurotoxins bind specifically to the nicotinic acetylcholine receptor in the postsynaptic membrane of skeletal muscles, thus preventing the binding of the chemical neurotransmitter acetylcholine and thereby blocking the excitation of muscles. This block at the neuromuscular junction leads to flaccid paralysis and lead to respiratory failure (45).

Alkanna orientalis treatment provide a protective effect against *Cerastes cerastes*

venom hepatotoxicity as, *Boraginaceae* family especially (*Alkanna orientalis* and *Echium humile*) rich with alpha linolenic acid (ALA), gamma linolenic acid (GLA), stearidonic acid (SDA), flavonoids in addition to rosmarinic acid (RA), all previous compounds have a powerful antioxidant properties and anti inflammatory effect. Also, flavonoids was reported as strongly inhibits the group II PLA₂ from *Vipera* and it weakly inhibits the group I PLA₂ from *Naja naja* (22). Therefore, they can restore the hepatic toxicity of *Cerastes cerastes* venom (16-19).

On the same pattern, the protective effect of *Alkanna orientalis* extract against the significant decrease in cholinesterase and the cholinergic effect of *cerastes cerastes* venom are in full agreement with Diab et al. (46). As they described the protective effect of *Echium humile* extract (family: *Boraginacea*) against malathion neurotoxicity and against the significant decrease in cholinesterase as a result of malathion cholinergic effect. In addition, the antagonist effect of *Alkanna orientalis* extract to cholinergic toxicity may be because of flavonoids inhibition to group II PLA₂ from *Cerastes cerastes venom* that responsible for the major neurotoxicity of *Cerastes cerastes* venom (22).

The significant decrease in red blood cells and hemoglobin level that was reported in this study could be attributed to the intravascular hemolysis due to the venom indirect hemolytic activity, the micro thrombin formation with disruption of erythrocytes in the microvasculature (47) and a physiological stress that result from the envenomation (48). The observed decrease in platelets count that caused by the crude venom may be a result of some enzymes that have a major effect on platelets such as serine proteinases and phospholipases A₂ enzymes (49). Another acceptable cause for the decreasing in platelets count may be because of the consumption of platelets due to hemorrhagic metalloproteinases effect on blood vessels damaging and rupturing them. Due to this rupture, platelets migrate to the lesion site and can bind to sub endothelial surfaces to form a haemostatic plug, which lead to the decreasing in platelet count (47,49).

In contrast, WBCs count increased significantly 2 hours after venom injection. This explained by the temporary immune response to crude venom that leads to liberation of white blood cells (50). Another acceptable hypothetical reason is that crude venom stimulates the liberation of pro-inflammatory cytokines by macrophages that responsible for the mobilization of both lymphocytes and monocytes (40). As well as, 2 hours after envenomation, the envenomed group showed a significant decrease in plasma prothrombin and partial thromboplastin concentration. This haemostatic disturbance may refer to the efficacy of C-type lectins, which considered a group of proteins that form about 2% of *Cerastes cerastes* venom (51). In addition, C-type lectins are responsible for the activation and inhibition of coagulation factors (52).

In addition, phospholipases A₂ display anticoagulant efficiency by suppressing the exterior passage of the haemostatic cascade. These groups of proteins can extend their activities by hydrolyze phospholipids or by overlapping with coagulation factor Xa and overlapping with its interaction with factor Va resulting in suppression of prothrombinase complex (48,53). These classes of protein comprise 19% of *Cerastes cerastes* venoms (51). The present study display that treatment with *Alkanna orientalis* was effective in restoring the depressed hematological parameters as well as leukocytosis due to the anti inflammatory, anti oxidative, antibacterial, and antiviral activities of *Alkanna orientalis* which rich in RA (19). RA has been reported to block both metalloproteinase and phospholipases A₂ (20). Therefore, *Alkanna orientalis* can prevent most hazardous hematological effect of *Cerastes errastes* crude venom.

The injection of rats with *cerastes cerastes* venom (i.p.) resulting in severe internal hemorrhage in the abdominal cavity because *Cerastes cerastes* crude venom contains 70% metalloproteinases, serine proteinases and 57.3% of hemorrhagic metalloproteinases P-III (51). These metalloproteinases exhibit proteolytic effects, leading to local hemorrhages because of the degeneration of vascular endothelium (54). As well as, serine proteases

and phospholipases A₂ are able to form proteins that effect platelet aggregation, fibrinolysis and cascade of coagulation as well as, the complement system (55). On the other hand, *alkanna orientalis* extract when given orally 2 hours before *Cerastes cerastes* venom injection or (i.p.) immediately after *Cerastes cerastes* venom injection was able to minimize the hemorrhagic effect of the venom. As, it able to antagonize the hematological toxicity by preventing the thrombocytopenic effect of the venom as well as, preventing sever depression in prothrombin and partial thromboplastin concentration that considered the major cause of the internal hemorrhage .

On the same pattern, when *Cerastes cerastes* antivenom immunoglobulin was injected intraperitoneal immediately after *Cerastes cerastes* venom injection, was able to minimize the hazardous venom hepatic and hematological effects. Antivenom reported as the specific antidote that prevents mortality and reduces hospital stay and morbidity, incase of snakebites (56). Antivenom is not compound that can cure or rollback the effects of snake venom, all they can do is to halt the effect of further activity of the snake antigens in the blood stream. Besides that, antivenom immunoglobulin therapy may cause a hypersensitive reaction in the body. This is called anaphylaxis that caused by the antibodies and other substances found in the blood-donor animals serum during antivenom synthesis (56). Hence, the creativity of this this work is the presentation of a new safe therapy for *Cerastes cerastes* venom with antidotal effect that clearly from previous results to be better than antivenom immunoglobulin therapy.

Conclusion

The natural medical herbs are showing a new area for development of better therapeutic and prophylaxis agents against expected envenomation by *Cerastes cerastes* venom toxicity. The alcoholic extract of *Alkanna orientalis* has many benefits, as it is cheap, easily available as it widely distributed in Saint Catherine (Egypt), stable at room temperature and able to antagonize the hazardous toxic effect of *Cerastes cerastes* venom. Therefore, we recom-

mend the usage of *Alkanna orientalis* extract as initial assist in *Cerastes Cerastes* bitten victims therapy to minimize mortality and morbidity. As well as, this extract can be used as a prophylaxis for researchers who work in the fields where *Cerastes cerastes* are abundant.

Conflict of interest

The authors have declared no conflict of interest

References

1. Molander M, Saslis-Lagoudakis CH, Jager AK, Ronsted N. Cross cultural comparison of medicinal floras used against snakebites. *J Ethnopharmacol* 2012; 139: 863–72.
2. Kasturiratne A, Wickremasinghe AR, Silva N, Gunawardena NK, Pathmeswaran A, Premaratna R, Savioli L, Laloo DG, de Silva HJ. The global burden of snakebite: A literature analysis and modelling based on regional estimates of envenoming and deaths. *PLoS Med* 2008; 5: 1591–604.
3. Saleh MA. Amphibians and Reptiles of Egypt. Publication of National Biodiversity Unit No. 6, Ministry of State Environmental Affairs, Egyptian Environmental Affairs Agency, Egypt, 1997.
4. Anai K, Sugiki M, Yoshida E, Maruyama M. Neutralization of a snake venom hemorrhagic metalloproteinase prevents coagulopathy after subcutaneous injection of *Bothrops jararaca* venom in rats. *Toxicon* 2002; 40: 63–8.
5. Kebir-Chelghoum H, Laraba-Djebari F. Cytotoxicity of *Cerastes cerastes* snake venom: Involvement of imbalanced redox status. *Acta Trop* 2017; 173: 116–24.
6. Ibrahim AM, ElSefi TT, Ghanem M, Fayed AM, Shaban NA. A horned viper bite victim with PRES. *Case reports in neurological medicine*. 2017; 2017. Article ID 1835796, 6 pages
7. Leon G, Valverde JM, Rojas G, Lomonte B, Gutierrez JM. Comparative study on the ability of IgG and Fab sheep antivenoms to neutralize local hemorrhage, edema and myonecrosis induced by *Bothrops asper* (terciopelo) snake venom. *Toxicon* 2000; 38: 233–4.
8. Girish KS, Kemparaju K. Inhibition of *Naja naja* venom hyaluronidase role in the management of poisonous bite. *Life Sci* 2006; 78: 1433–40.
9. Girish KS, Kemparaju K. The magic glue hyaluronan and its eraser hyaluronidase: a biological overview. *Life Sci* 2007; 80 (21): 1921–43.
10. De Smet, PA. The role of plant derived drugs and herbal medicines in health care. *Drugs* 1997; 54 (6): 801–40.
11. (11)Hasani-Ranjbar S, Larijani B, Abdollahi M. A systemic review of potential herbal sources of future drugs effective in oxidant related diseases. *Allergy Drug targets* 2009; 8 (1): 2–10.
12. Moallem SA, Hosseinzadeh H, Ghoncheh F. Evaluation of Antidepressant Effects of Aerial Parts of *Echium vulgare* on Mice. *Iran J Basic Med Sci* 2007; 10 (3): 189–96.
13. Aung HT, Nikai T, Niwa M, Takaya Y. Rosmarinic acid inhibits *Argusia argentea* snake venom-induced hemorrhage. *J Nat Med* 2010; 64 (4): 482–6.
14. Sekhar J, Panchala G, Sudarsanam G, Prasad GP. Ethnic information on treatment for snake bites in kadapa district of Andhra Pradesh. *Life Science Leaflet* 2011; 12: 368–75.
15. Gomes A, Das R, Sarkhel S, Mishra R, Mukherjee S, Bhattacharya S, Gomes A. Herbs and herbal constituents active against snakebite. *Indian J Exp Biol* 2010; 48 (9): 865–78.
16. Lopez-Martinez JC, Campara-Madrid P, Guil-Guerrero JL. Linolenic acid enrichment from *Borago officinalis* and *Echium fastuosum* seed oils and fatty acids by low temperature crystallization. *J Biosci Bioeng* 2004; 97 (5): 294–8.
17. Abbaszadeh S, Radjabian T, Taghizadeh M, Fazeli F, Salmaki Y. Characterization of fatty acids in different organs of some Iranian *Echium* plants. *J Med Plants Res* 2011; 5 (19): 4814–21.
18. Kuhnt K, Degen C, Jaudszus A, Jahreis G. Searching for health beneficial n-3 and n-6 fatty acids in plant seeds. *Eur J Lipid Sci Technol* 2012; 114 (2): 153–60.
19. Petersen M, Simmonds MS. Rosmarinic acid. *Phytochem* 2003; 62 (2): 121–5.
20. Ticli FK, Hage LI, Cambraia RS, Pereira PS, Magro AJ, Fontes MR, Stábeli RG, Giglio JR, França SC, Soares AM, Sampaio SV. Rosmarinic acid, a new snake venom phospholipase A2 inhibitor from *Cordia verbenacea* (Boraginaceae): antiserum action potentiation and molecular interaction. *Toxicon* 2005; 46 (3): 318–27.
21. El Sohly HN, El-Ferally FS, Joshi AS, Walker LA. Antiviral flavonoids from *Alkanna orientalis*. *Planta Medica* 1997; 63: 384.
22. Gopi K, Renu K, Jayaraman G. Inhibition of *Naja naja* venom enzymes by the methanolic extract of *Leucas aspera* and its chemical profile by GC-MS. *Toxicol Rep* 2014; 1: 667–73.

23. Ramakrishnan M A . Determination of 50% endpoint titer using a simple formula. *World J Virol*: 2016; 5: 85–6.
24. Sukhdev SH, Suman PS, Gennaro L, Dev DR. Extraction technologies for medicinal and aromatic plants. United Nation Industrial Development organization and the international center for Science and High Technology. 2008; 116.
25. Reitman S, Frankel SA. Colorimetric method for the determination of serum glutamic oxaloacetic and glutamic transaminase. *Amer Clin Pathology* 1957; 28 (1): 56–63.
26. Moss DW, Henderson AR, Kachmar JF. Enzymes. In: Tietz NW, ed. *Fundamentals of Clinical Chemistry*. 3rd ed. Philadelphia: WB Saunders 1987: 346–421.
27. Doumas B, Watson W. Enzymatic colorimetric method of albumin. *Clin Chem Acta* 1971; 31: 87–96.
28. Tietz NW. *Fundamentals of Clinical Chemistry*: 2 nd ed. Tietz NW, editor, 1994, pp 692.
29. EllmanGL, Courtney KD, Andrea V, Featherstone RM. A new and rapid colorimetric determination of acetylcholinesterase activity. *Biochem Pharmacol* 1961; 7: 88–95.
30. Colman RW, Hirsh J, Marder VJ, Salzman EW. *Hemostasis and Thrombosis: Basic Principles and Clinical Practice*. Philadelphia: JB Lippincott, 1994: 1. 21.
31. Van Kampen EJ, Zijlstra WG. Determination of hemoglobin and its derivatives. *Adv Clin Chem*. 1965; 8: 141–87.
32. Dacie J V, Lewis S M: *Practical haematology*. 7th Edition (1991). Churchill Living Stone, Edinburgh, pp. 41–57.
33. Duncan DB. Multiple range and multiple F tests. *Biometrics* 1955; 11 (1): 1–42.
34. Armitage P, Berry G. *Statistical Methods in Medical Research*. Boston MA: Blackwell Scientific, Oxford, UK, 1987; 559.
35. Salman MM. Effects of Different Doses of *Cerastes cerastes* Crude Venom on Biochemical Parameters in Serum of Guinea pigs at different times. *Biological Forum* 2014; 6 (2): 329–39.
36. Al-Sadoon MK, Abdel Moneim AE, Diab MM, Bauomy AA. Hepatic and renal tissue damages induced by *Cerastes cerastes* gasperetti crude venom. *Life Sci J* 2013; 10 (4): 191–7.
37. Shaban EA, Hafez MN. Ability of gamma irradiated polyvalent antivenin to neutralize the toxicity of the Egyptian cobra (*Naja haje*) venom. *Egypt J Hosp Med* 2003; 13: 135–52.
38. Abdel Moneim AE, Othman MS, Mohmoud SM, El-Deib KM. Pomegranate peel attenuates aluminum-induced hepatorenal toxicity. *Toxicol Mech Methods* 2013; 23 (8): 624–33.
39. Mohamed AH, Fouad S, El-Assar AM, Salem A, Abdel Aal A, Hassan AA, Zahran F, Abbas N. Effects of several snake venoms on serum and tissue transaminase, alkaline phosphatase and lactate dehydrogenase. *Toxicon* 1981; 19 (5): 605–.
40. Al-Sadoon MK, Fahim A Possible recovery from an acute envenomation in male rats with LD50 of *Echis coloratus* crude venom: IA seven days hematological follow-up study. *Saudi Biol Sci* 2012; 19 (2): 221–7.
41. Al-Quraishy S, Dkhill MA, Abdel Moneim AE. Hepatotoxicity and oxidative stress induced by *Naja haje* crude venom. *Venom Anim Toxins Incl Trop Dis* 2014; 20 (1): 42–52.
42. Soares AM, Giglio JR. Chemical modifications of phospholipases A2 from snake venoms: effects on catalytic and pharmacological properties. *Toxicon* 2003; 42 (8), 855–68.
43. Kini RM. Excitement ahead: structure, function and mechanism of snake venom phospholipase A2 enzymes. *Toxicon* 2003; 42 (8): 827–40.
44. Schneemann M, Cathomas R, Laidlaw ST, El Nahas AM, Theakston RD, Warrell DA. Life-threatening envenoming by the Saharan horned viper (*Cerastes cerastes*) causing micro-angiopathic haemolysis, coagulopathy and acute renal failure: clinical cases and review 2004. *QJM* 97; (11): 717–27.
45. Chang CC. The action of snake venoms on nerve and muscle. In *snake venoms, handbook of experimental pharmacology*. Vol. 52. (ed: C.Y.Lee), pp. 309–376. Springer-Verlag, Berlin, , Heidelberg, New York.
46. Diab AA, Dahmy SI , Soliman. SAI and Nasser M M. The protective role of *Echium humile* extract against toxicity induced by insecticide (malathion) in male albino rats. *Journal of American Science* 2013; 9 (11): 259–67.
47. Izidoro LFM, Rodrigues VM , Rodrigues RS, Ferro EV, Hamaguchi A , Giglio JR, Homs-Brandeburgo MI. Neutralization of some hematological and hemostatic alterations induced by neuwiedase, a metalloproteinase isolated from *Bothrops neuwiedi pauloensis* snake venom, by the aqueous extract from *Casearia mariquitensis* (Flacourtiaceae). *Biochimie* 2003; 85 (7): 669–75.
48. Kini R M. Toxins in thrombosis and haemostasis: potential beyond imagination. *J Thromb Haemost* 2011; 9: 195–208.
49. Pidade-Queiroz, G , Magnoli FC, Portaro FCV, Serrano SMT, Lopes AS, Leme AF, van den

Berg CW, Tambourgi DV. PI snake venom metalloproteinase is able to activate the complement system by direct cleavage of Central components of the Cascade. *PLoS Negl Trop Dis* 2013; 7 (10): 2519.

50. Amin MR, Mamun SMH, Rashid R, Rahman M, Ghose A, Sharmin S, Rahman MR, Faiz MA. Anti-snake venom: use and adverse reaction in a snake bite study clinic in Bangladesh. *J Venom Animals Toxins Incl Trop Dis* 2008; 14 (4): 660–72.

51. Makran B, Fahmi L, Pla D, Sanz L, Oukkache N, Lkhider M, Ghalim N, Calvete JJ. Snake venomomics of *Macrovipera mauritanica* from Morocco, and assessment of the para-specific immunoreactivity of an experimental monospecific and a commercial antivenoms. *J Proteomics* 2012; 75 (8): 2431–41.

52. Morita T. Structure-function relationships of C-type lectin-related proteins. *Pathophysiol Haemost Thromb* 2005; 34 (4-5): 156–9.

53. Venkatesh M, Gowda V. Synergistically acting PLA2: peptide hemorrhagic complex from *Daboia russelii* venom. *Toxicon* 2013; 73: 111–20.

54. Fox JW, Serrano SM. Timeline of key events in snake venom metalloproteinase research. *J Proteomics* 2009; 72 (2): 200–9.

55. Sajevic T, Leonardi A, Križaj I . Haemostatically active proteins in snake venoms. *Toxicon* 2011; 57 (5): 627–45.

56. Persson H. Envenoming by European vipers: antivenom treatment-influence on morbidity. *Przegląd Lekarski*. 2001; 58 (4): 223–5.