

# AN ALTERNATIVE ANTIVIRAL THERAPY OF NEWCASTLE DISEASE IN BROILER CHICKENS: A CLINICAL STUDY OF METHANOLIC *NEEM* LEAVES EXTRACT

Sawsan Elbasuni<sup>1\*</sup>, Mai Osman<sup>2</sup>, Reem Soliman<sup>3</sup>, Yasmeeen Magdy<sup>4</sup>, El-Hadary Abdalla<sup>5</sup>, Reda Fathy<sup>1</sup>

<sup>1</sup>Avian and Rabbit Diseases Department, <sup>4</sup>Department of Anatomy, <sup>5</sup>Biochemistry Department, Faculty of Veterinary Medicine, Benha University, Benha 13736, <sup>2</sup>Biochemistry, Toxicology and Nutritional Deficiency Diseases Department, Animal Health Research Institute, Benha Branch, <sup>3</sup>Evaluation of Inactivated Viral Poultry Vaccines Department, Central Laboratory for Evaluation of Veterinary Biologics, Agriculture Research Center (ARC), Egypt

\*Corresponding author, E-mail: owsan.mohamed@fvvm.bu.edu.eg

**Abstract:** Newcastle disease (ND) is an important viral disease that threatens the global poultry industry. The urgent need for a safe and effective antiviral alternative prompted us to evaluate neem methanolic leaf extract against Newcastle disease virus (NDV) in broilers. A total of Sixty Cobb chicks (day old) were allocated randomly into 4 equal groups; group A was a control negative, and group B was a control positive. Groups C and D received a methanolic neem leaf extract (MNLE) in drinking water for five days at 500 and 1000 µg/kg BW, respectively. At 25<sup>th</sup> days old, chicks in groups B, C and D were challenged via the oculonasal route with 0.2 ml of virulent NDV. The use of MNLE in groups C and D significantly reduced morbidity and mortality as well as the macroscopic and microscopic scoring lesions of all examined organs compared to the infected untreated group B. The high dose of MNLE (1000 µg/ kg BW; group D) was more efficient and significant in relieving the clinical and pathological abnormalities caused by ND challenge compared with the low dose (500 µg/ kg BW; group C). Moreover, positive effects of the herbal treatment on the experimentally ND-infected chickens were evidenced by reducing viral RNA concentrations in the oropharyngeal swabs at 3, 5, and 7 days post challenge and the infectivity titer of the virus isolated from the trachea, spleen, and cecal tonsils at 7 days post challenge. In conclusion, the study showed that MNLE had a positive and helpful role in the control of NDV infection and shedding. So, MNLE could be a source of inspiration for new alternative antivirals.

**Key words:** Newcastle disease; broilers, *Azadirachta Indica*; *Neem*; methanolic extract; antiviral

## Introduction

Newcastle disease (ND) is a highly contagious viral disease of poultry affecting the respiratory, gastrointestinal, nervous, and reproductive systems. It leads to serious health consequences such as high morbidity and mortality, increased veterinary management costs, and long-term restrictions on international trade (1-2). Although ND was initially identified in 1926 as caused by

avian paramyxovirus type 1, it continues to spread worldwide in both endemic and epidemic forms (3). There have been four defined panzootic ND, and the existence of a fifth panzootic was predicted to cause uncontrollable severe ND outbreaks by the current preventive strategies due to the rapid spread of new velogenic NDV VII sub-genotypes through Asia and the Middle East that threaten the poultry industry. Vaccination with live and inactivated NDV vaccines is the only commercial control measure, which does not always give complete protection to birds (4-5). As the world changes toward using safe herbs with historic medical properties, several screening

studies and in vitro tests have been conducted to determine how well different herbs and their extracts fight viruses, especially NDv. Medicinal plants are antiviral alternatives, such as *Momordica balamina*, *Adansonia digitata*, *Artemisia annua*, *Azadirachta indica*, *Psidium guajava*, *Moringa oleifera* (6).

*Azadirachta indica* (Neem), a Meliaceae member, was used extensively in all Ayurvedic, Unani, and Chinese medicine to cure and prevent diseases because of being a rich source of antioxidants and other wide variety of bioactive compounds (7). This plant's leaves hold a variety of constituents, such as nimbin and its derivatives (nimbinene, 6-desacetyl-N-methylnimbinene, nimbandiol, nimbolide), ascorbic acid, and amino acids (as n-hexacosanol and 17-hydroxyazadiradione). Polyphenolic flavonoids, such as quercetin, and  $\beta$ -sitosterol purified from neem leaves, have been shown by in vitro tests to have effective antiviral, antibacterial, and antifungal activities (8-9).

Antiviral activity of variable neem extracts has been previously documented against hepatitis C, human immunodeficiency virus, herpes, Dengue, Japanese encephalitis virus, coronaviruses, NDv, infectious bursal disease virus, and influenza viruses (10-16). Where several extractives of each of the neem parts as leaves, fruits, and bark, become known to have Invitro and Invivo antiviral activities against NDv and others in the culture of VERO cells and chicken embryos via virus inactivation and yield reduction besides interfering with their replication (7, 16). According to Helmy (16), the NDv replication in VERO cells and chicken embryos was fully inhibited with the methanol extract of neem leaves at concentrations of 3- 4  $\mu\text{g/ml}$  and 4  $\mu\text{g/egg}$ , respectively with the absence of cytotoxicity. The need for a specialized antiviral appears urgent with the frequent NDv epidemics facing poultry. This prompted us to apply a clinical evaluation of the methanolic neem leaves extract against Newcastle disease virus in broilers as an effective antiviral alternative from nature.

## Material and methods

### *Preparation and analysis of methanolic Azadirachta Indica extract*

Neem (*Azadirachta Indica*) leaves were collected from the faculty of Agriculture at Moshtohor,

Benha University. Neem leaves dried under shade and ground efficiently to be a fine powder. Soak dried neem powder at room temperature for 24 hours in HPLC-grade methanol (80%) at a ratio of 1:5 and the mixture filtered. The obtained filtrate was concentrated at 45° C under a vacuum using a rotary evaporator. The obtained methanol neem leaves extract (MNLE) was emulsified in 20% dimethyl sulfoxide for the subsequent studies (17). Total phenolic and flavonoid contents were determined in the obtained extract that expressed as equivalents to gallic acid (GAE) and quercetin (QE), respectively. In addition, the antioxidant activities were assayed using ABTS and DPPH radical scavenging tests (18-19).

### *Challenge Virus*

Virulent NDv isolate (NDV/CH/EG-Q/11/2018) belonged to class II (genotype VII) with accession No MN137991. The virus was kindly provided in the form of infectious allantoic fluid from our colleague Asmaa Desouky, Department of Avian and Rabbit Diseases, Faculty of Veterinary Medicine, Benha University. Later, virus was propagated ( $10^{8.5}$  EID<sub>50</sub>/0.1ml) in the laboratory of Newcastle Department, Veterinary Serum and Vaccine Research according to OIE, (2).

### *Experimental design*

The experiment was conducted at the Laboratory Animal Research Center, Faculty of Veterinary Medicine, Benha University. All procedures used in this experiment were approved by the Institutional Animal Care and Use Committee of Benha University and followed the guidelines of the National Institute of Health in Egypt (Ethical No. BUFVTM 07-11-21).

A total of sixty Cobb chicks (day old) were obtained from a local hatchery in Egypt and allocated randomly into 4 equal groups of 15 birds as follows; group A was as control negative without any treatment, and group B was as control positive challenged untreated group. Groups C and D were challenged and received the prepared neem leaves extract in the drinking water for five days starting from the day of infection at a dose of 500 and 1000  $\mu\text{g/kg BW}$ , respectively. At 25<sup>th</sup> days old, chicks in groups B, C and D were challenged via the oculonasal route with 0.2 mL of virulent NDv class II (genotype VII) with titer

of  $10^6$  EID<sub>50</sub>/chick (20). All chicks were observed during the trial and examined for clinical signs, and postmortem lesions. Morbidity and mortality were recorded daily.

### *Parameters evaluating the efficacy of the methanolic neem leaves extract*

#### *Clinicopathological examination and lesion scoring*

At 7 days post challenge (dpc), clinical and postmortem examination was applied on three humanely slaughtered birds from each group. The trachea, lung proventriculus, intestine, cecal tonsils, spleen, and kidneys were examined macroscopically and scored from 0 to 3 according to the lesion severity (21). Part of the trachea, proventriculus, cecal tonsils, and spleen were collected for the histopathological examination. These tissue samples were fixed in 10% formalin, then dehydrated in the grades of alcohol concentrations, cleared in xylene, and embedded in molten wax. Sections of 5  $\mu$ m thick were made and finally stained by H and E. The stained slides were examined microscopically, and lesion scoring was applied (21).

#### *Viral shedding*

At 3, 5, and 7 dpc, five oropharyngeal swabs were collected from each group to estimate the virus shedding using reverse transcription-Real time polymerase chain reaction (RRT-qPCR) as follows; Total RNA was extracted from 500  $\mu$ l of the prepared oropharyngeal swabs using the RNeasy® Mini Kit (Qiagen). RT-qPCR experiment was performed in a Bio-Rad real-time thermal cycler CFX96™ using primers for Matrix gene of NDv (Forward; 5'-CCT GAG GAG AGG ATT TGC TA-3' & reverse; 5'-AGT GAT GTG CTC GGA CCT TC-3'; and probe (5'-[FAM] TTC TCT AGC AGT GGG ACA TGC [TAMRA]-3' that were designed by Wise et al., (22). TOPreal™ One-step RT-qPCR kit (enzymomics) was used in the amplification. All procedures were conducted according to the manufacturer's instructions. For primer set, the RT step was 30 min at 50°C, followed by 15 min at 95°C. The cycling conditions for the APMV-1 matrix primers consisted of 40 cycles of 10 s of denaturation at 94°C, 30 s of annealing at 58°C,

and extension at 72°C for 10 s. Samples were always run-in triplicate to test for reproducibility. Challenge NDv strain was used for positive control and for the determination of the limit of detection for the assay. RNA concentration was quantified by the cycle threshold (Ct) method and interpreted versus the standard curve to NDv EID<sub>50</sub> (22).

Infectivity titer of the challenged virus in SPF eggs embryos

Three samples of trachea, spleen and cecal tonsils from each group were collected at 7 dpc and prepared to estimate the infectivity titer of the challenged virus in SPF eggs embryos as follows; Each clarified homogenate sample was diluted in sterile phosphate buffer saline (PBS) twelve fold serial dilution (1 part of sample to 9 part of PBS), and each dilution was injected in five SPF embryonated chicken eggs via the allantoic cavities at a dose of 0.2 ml per egg. The negative control eggs were injected with physiological saline. All the eggs were incubated at 37°C. All the embryos that died on the first day were discarded. The infectivity titer was calculated using the Reed and Muench (23) method and expressed in log<sub>10</sub> EID<sub>50</sub>/ml.

#### *Statistical analysis*

Data were analyzed by one way ANOVA, and by multiple repeated measures for viral shedding using SPSS 16, (2007) to determine the differences between individual treatments and corresponding controls. Results were represented as means  $\pm$  standard error.

## **Results**

### *Total phenolic and flavonoid contents and antioxidant activities of neem leaves*

The extraction yield of neem leaves was 11.93 g/100 g on a dry weight basis. Total phenolic and flavonoid contents in each gram of MNLE were estimated as 82.1 mg GAE and 105.30 mg QE, respectively. Moreover, ABTS and DPPH radical scavenging activities of MNLE were detected as 61.25 and 63.18 %, respectively.

*Effect of methanolic neem leaves extract on clinical and pathological outcomes after NDv challenge*

The challenge of 25-day-old broilers by NDv genotype VII resulted in depression, ruffled feathers, conjunctivitis, and nasal discharge beginning at the 3<sup>rd</sup> dpc in all experimentally infected groups (B, C, and D). At the 5<sup>th</sup> dpc, birds in the challenged groups showed swollen heads, sneezing, rales, and greenish diarrhea that involved 100 % of the challenged birds in the positive control group (B), and the mortalities started early in this group to reach 60 %. Postmortem examination of dead birds revealed congestion of musculature and trachea with marked hemorrhages on the proventriculus, small intestine, cecal tonsils, and rectum. On day 7 post-challenge, birds in positive control group B reported significant pathological changes with the highest lesion scores, including congestion in

trachea and lungs; edematous and hemorrhagic proventriculus; hemorrhagic ulcers along the intestine and cecal tonsils; mottled spleen and inflamed kidneys (Figure 1; Table 1). On the other side, all birds in group A (negative control) appeared clinically healthy throughout the experiment.

Using MNLE at 500 and 1000 µg/ kg BW for five successive days to control the ND infection in groups C and D, morbidity and mortality rates lowered to 74 & 53.3% and 26.67 & 20 %, respectively. As shown in Table (1) and Figure (1), significant decreases in total lesion scoring were reported for all organs examined from groups C and D treated with MNLE when compared with those of the positive control group (B). The high dose of MNLE (1000 µg/ kg BW; group D) was more efficient and significant in relieving the clinical and pathological abnormalities caused by ND challenge when compared with the other dose given to birds in group C (500 µg/ kg BW).

**Table 1:** Effect of methanolic neem leaf extract on the clinical and pathological outcomes the broilers challenged with Newcastle disease virus

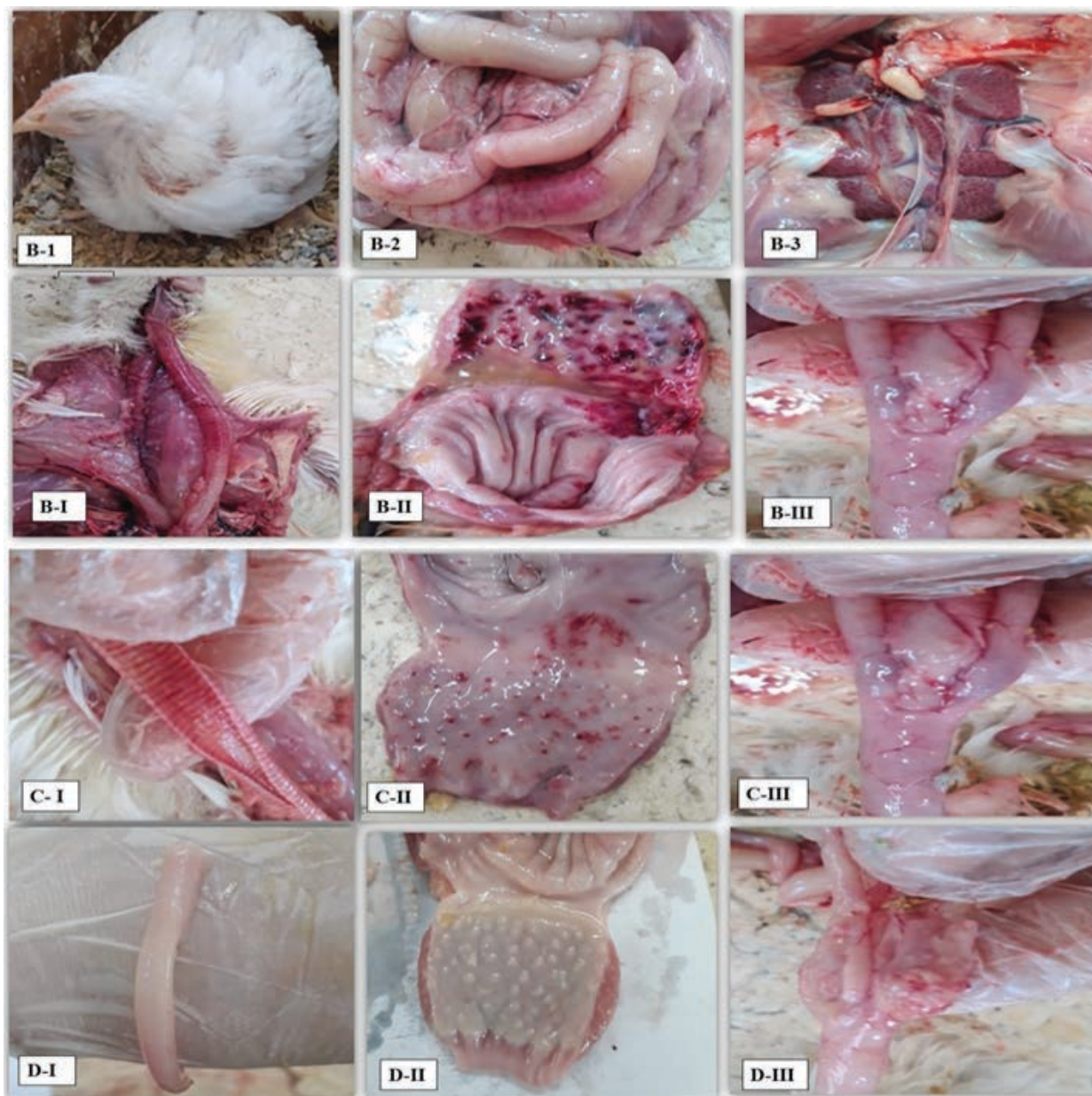Items		Experimental groups				
		Group A (-ve)	Group B (+ve)	Group C (500 µg/ kg BW)	Group D (1000 µg/ kg BW)	
<b>Morbidity rate</b>		0	100 %	74 %	53.3%	
<b>Clinical findings*</b>	<b>Ruffled feathers and de-pression.</b>	0	15/15	11/15	8 /15	
	<b>Conjunctivitis and nasal discharges</b>	0	15/15	10/15	9 /15	
	<b>Swollen head.</b>	0	7/15	3/15	1/15	
	<b>Greenish diarrhea</b>	-	++	+	+	
<b>Mortality rate</b>		0	60 %	26.67%	20%	
<b>Le-sion scoring ‡</b>	<b>Macroscopic</b>	<b>Trachea</b>	0 <sup>d</sup>	3 <sup>a</sup>	2.33±0.33 <sup>ab</sup>	1.67±0.33 <sup>c</sup>
		<b>Lung</b>	0 <sup>d</sup>	2.67±0.33 <sup>a</sup>	1.67±0.33 <sup>b</sup>	1 <sup>c</sup>
		<b>Proventriculus</b>	0 <sup>d</sup>	3 <sup>a</sup>	2 <sup>b</sup>	1.33±0.33 <sup>c</sup>
		<b>Intestine</b>	0 <sup>d</sup>	3 <sup>a</sup>	2 <sup>b</sup>	1±0.58 <sup>c</sup>
		<b>Cecal tonsils</b>	0 <sup>d</sup>	3 <sup>a</sup>	1.67±0.33 <sup>c</sup>	0.67±0.33 <sup>c</sup>
		<b>Spleen</b>	0 <sup>c</sup>	2.33±0.33 <sup>a</sup>	1 <sup>b</sup>	0.33±0.33 <sup>bc</sup>
		<b>Kidney</b>	0 <sup>c</sup>	2.67±0.33 <sup>a</sup>	1 <sup>b</sup>	0 <sup>c</sup>
	<b>Micro-scopic</b>	<b>Trachea</b>	0 <sup>c</sup>	4.33±0.33 <sup>a</sup>	2 <sup>b</sup>	1.67±0.33 <sup>b</sup>
		<b>Proventriculus</b>	0 <sup>c</sup>	3.67±0.33 <sup>a</sup>	2.33±0.33 <sup>b</sup>	2.33±0.33 <sup>b</sup>
		<b>Cecal tonsils</b>	0 <sup>c</sup>	3.33±0.33 <sup>a</sup>	2 <sup>b</sup>	1.33±0.33 <sup>b</sup>
		<b>Spleen</b>	0 <sup>d</sup>	3.67±0.33 <sup>a</sup>	2.67±0.33 <sup>b</sup>	1.67±0.33 <sup>c</sup>

Clinical signs were recorded as ruffled feathers, depression, conjunctivitis, nasal discharges, swollen head and green-ish diarrhea (No of affected chicks/ total No). ‡ Following slaughtering of selected birds; macroscopic and micro-scopic lesions as congestion, hemorrhages and so on were scored in the harvested organs (trachea, lungs, proventric-ulus, cecal tonsils, intestine, spleen, and kidney). Severity scores were absent (0); Mild (1); Moderate (2); Severe (3). Lesion scoring was expressed as mean ± standard error.

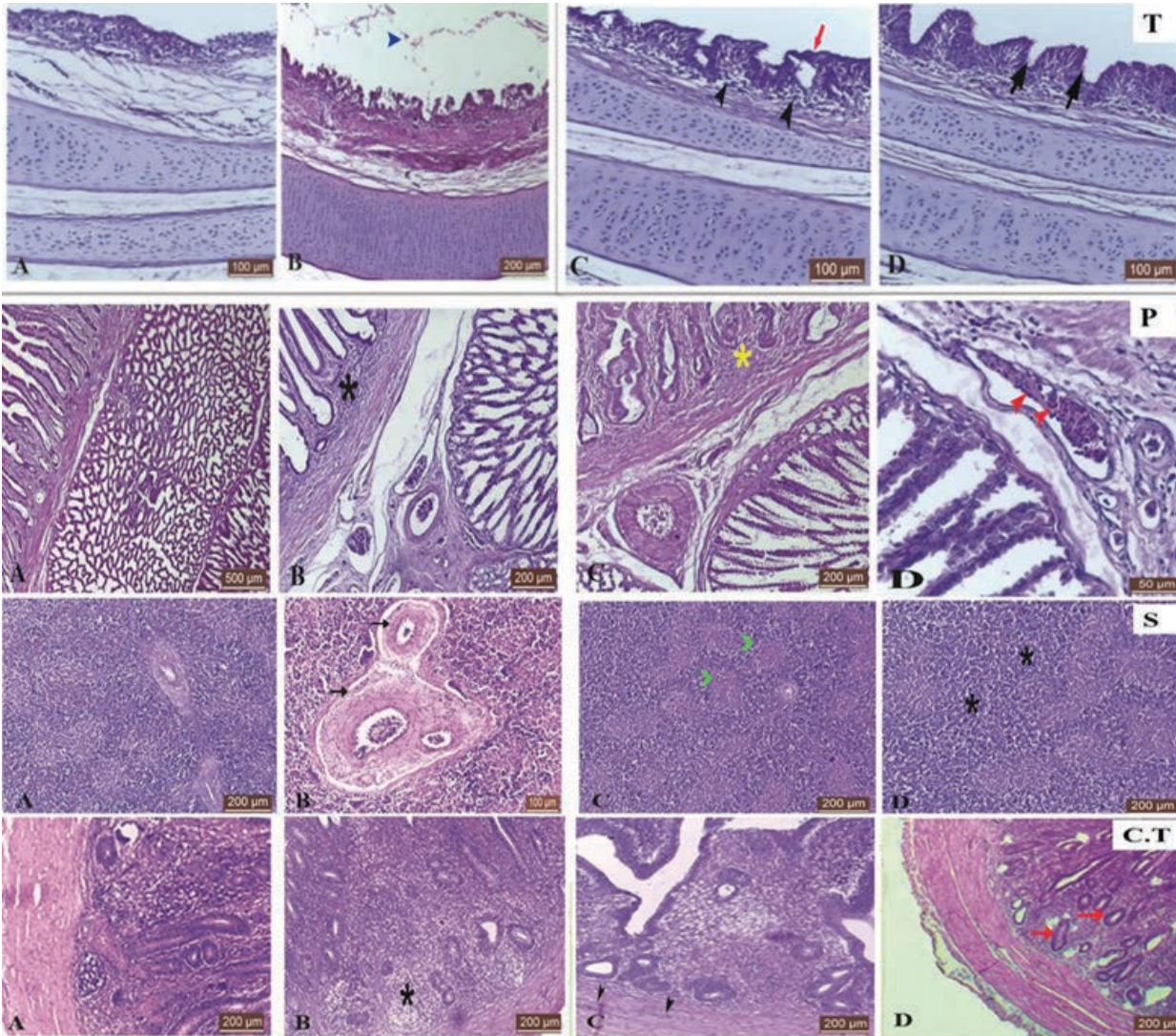
*Effect of methanolic neem leaves extract on the histopathological changes in broiler chicks after challenge with NDv*

Histopathological changes of the control and NDv-challenged chickens were analyzed on day 7 post challenge, as shown in Table (1) and Figure (2). No histological alterations were detected in all examined organs from control negative group A. Tracheal sections (T) of control positive group B showed hemorrhage and obvious epithelial desquamation in the tracheal lumen, in addition

to note of focal deciliated areas. Significant differences in the histological tracheal alterations score were evident between the treated groups C and D and the infected untreated group B. Similarly, treated group C and D proventricular (P) sections showed slight edema, congestion, and mild lymphocytic infiltration which significantly improved histological score when compared with group B (positive control sections) that showed severe mononuclear cell infiltration with severe hemorrhages and necrosis, loss of the lining epithelium, fusion, and shortening of the plicae.



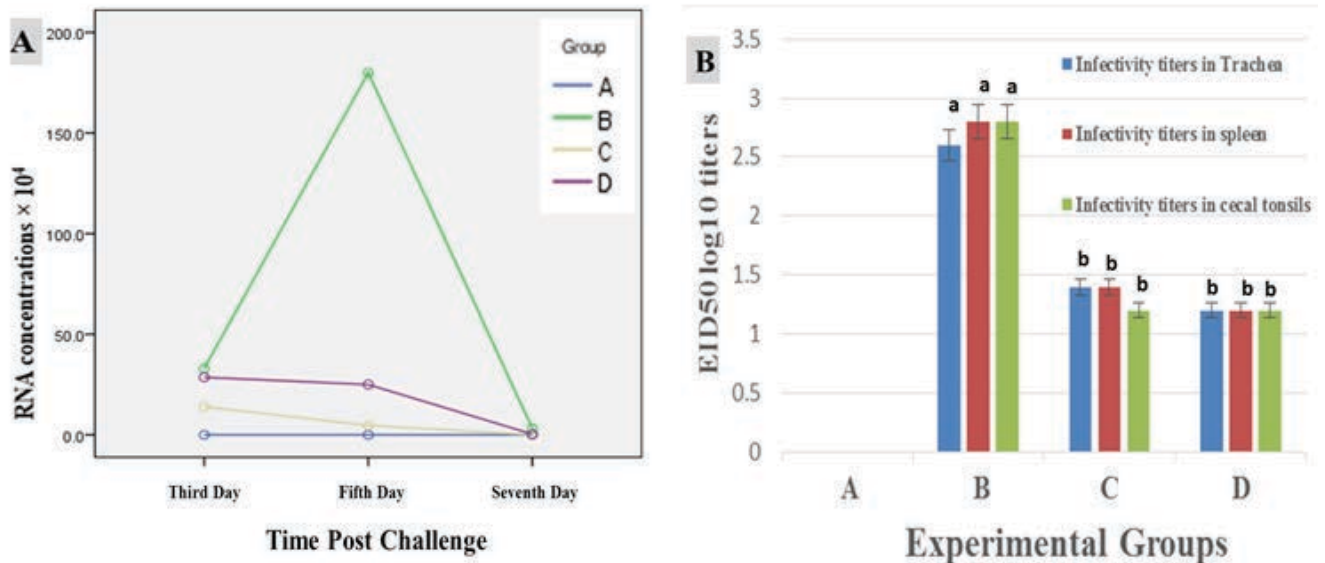
**Figure 1:** Clinicopathological picture of positive control group showing morbid bird with ruffled feathers, conjunctivitis, and nasal discharge (B-1); hemorrhagic ulcers along the intestine of dead bird (B-2) with inflamed kidneys (B-3). Moreover, several pathological lesions with varied scores were observed in the examined trachea (I), proventriculus (II), and cecal tonsils (III) of the experimental groups (B, C, and D) on day 7 post challenge with NDv



**Figure 2:** Histological H and E stained sections of the trachea (T), spleen (S), proventriculus (P), and cecal tonsils (C.T) from the experimental groups (A, B, C, and D) of the broilers on day 7 post challenge with NDv challenge; bar in photos indicates lens magnification. Tracheal sections (T) from control negative (A) showing apparent normal histological structure; control positive group (B) showing hemorrhage, deciliation and epithelial desquamation (blue arrowhead); (C) showing hyperemia and lymphocytic infiltration (black arrowhead) with focal areas of deciliation (red arrow) from group C, and (D) showing edema with no evidence of deciliation (black arrow) from group D. In proventriculus sections (P) were (A) control negative group showing apparent normal histological structure, (B) group B showing mononuclear cell infiltration (black star), (C) group C showing mild lymphocytic infiltration (yellow star), (D) group D showing lymphocytic infiltration and increased accumulated gland secretions (red arrowhead). Spleen sections (S) for control negative (A) showing apparent normal histological structure, (B) group B showing thickening of blood vessels wall (black arrow), (C) group C showing mild to moderate lymphocytic degeneration (green arrowhead), (D) of group D showing proliferated lymphoid follicles (black star). Sections of cecal tonsil (C.T); negative control (A) showing normal histology. (B) Group B showing mild lymphoid depletion, (C) group C showing mild transmural invasion of inflammatory cells with hemorrhages, and (D) group D showing few active follicles

Moreover, examination of the cecal tonsil (C.T) sections in the positive control group (B) showed severe transmural inflammatory cell invasion with increased bleeding, while C.T sections in treated groups C and D showed slight lymphatic depletion and mild intramural invasion of lymphocytes resulting in a significant decrease in their

scores compared to the positive control group B. Significance decrease in histopathological lesion scoring with efficient proliferation in lymphoid follicles were also observed in the spleen sections (S) of the treated groups (C and D) with comparison to the control positive group B that showed severe multifocal lymphoid depletion and diffuse necrosis.



**Figure 3:** Shedding and infectivity titration of Newcastle disease virus in different groups of broilers. (A) Mean viral nucleic acid concentration value of real time RT-PCR and equivalent EID<sub>50</sub>/mL of NDv genotype VII are detected in oropharyngeal swabs on days 3<sup>rd</sup>, 5<sup>th</sup>, and 7<sup>th</sup> post challenge and (B) Infectivity titers of reisolated NDv genotype VII from the trachea, spleen, and cecal tonsil in specific pathogen free chicken embryos on day 7<sup>th</sup> post challenge. Small letter (a, b) showed significant difference between the groups.

#### *Effect of methanolic neem leaf extract on viral shedding and infectivity titer after challenge with NDv*

The virus was shed early at the 3<sup>rd</sup> dpc from the oropharyngeal swabs of the control positive group B with mean RNA concentrations of approximately  $3.3 \times 10^5$  EID<sub>50</sub>/ml (Figure 3). Virus shedding continued on days 5 and 7 dpc with mean RNA concentrations of approximately  $1.8 \times 10^6$  and  $3.1 \times 10^4$  EID<sub>50</sub>/ml, respectively. Moreover, the challenged ND was reisolated in ECE with infectivity titers of  $10^{2.6}$ ,  $10^{2.8}$ , and  $10^{2.8}$  from the trachea, spleen, and cecal tonsils of the control positive group B at 7dpc, respectively. Worthily, the highest RNA concentrations and infectivity titers were reported in the positive control group (B) at all three interval periods. A significant decrease in the viral shedding and infectivity titer after challenge with NDv genotype VII was recorded in birds treated with the MNLE at two different doses in groups (C & D) compared with those of the control positive group (B). Interestingly, no significant difference was reported between the treated groups (C and D) and the negative control group (A) in the viral shedding at the 7<sup>th</sup> dpc. The challenged NDv and its RNA expressions were not detected in all examined samples from the negative control birds (group A).

#### Discussion

Newcastle disease is a transmissible and notifiable poultry disease in the OIE list A. It has the potential for severe and rapid spread, irrespective of national borders, adversely affecting global poultry production (24). Despite immunization and medication programs against ND, it causes yearly 40–60% of poultry losses (25). Most references to NDv in poultry are chicks, which are most affected. However, the severity of clinical signs does not vary only according to the inherent virulence of the virus but also according to some host-related factors such as age, route of infection, immune status, and concomitant environmental stress (4, 26). The infected untreated birds of the control positive group in the current study early showed the clinical signs of ND at 2 dpc as appetite loss, depression, greenish diarrhea, respiratory signs, and nervous signs, in addition to the morbidity and mortality rates in this group were more significant than control negative and other treated groups.

Moreover, we saw several notable pathological changes in different organs for NDv infection, such as congestion of musculature and trachea with marked hemorrhages on the proventriculus, small intestine, cecal tonsils, and rectum during necropsy. The histopathological examination

of the trachea, proventriculus, cecal tonsil, and spleen showed congestion, hemorrhages, and lymphocytic infiltrations. Similar observations of several organs were recorded previously in the field, and experimental ND infection (21, 26-29) was attributed to specific tropisms and the extensive dissemination of the velogenic ND strains to multiple body systems after initial replication (4).

Herbal extracts have been used medicinally since ancient times due to their antiviral potential and manageable side effects. Several neem extracts are known for their powerful therapeutic effect, which may be an excellent option for treating viral infections and protecting herds. For that, this work studied the impact of the methanolic neem leaves extract on the control of ND in broilers at doses of 500 and 1000 µg/kg BW (groups C and D). MNLE doses showed a delay in the onset of the disease. They significantly decreased mortalities, clinical signs, and pathological findings in the examined organs caused by ND challenge compared with the control positive group (B). This result was consistent with the findings of Tolba (29), who reported the protective efficacy of *Moringa Oleifera* extract in chickens against NDv infection without immunization. These findings were supported by previously report on the invitro ability of neem leaves to suppress several viruses as hepatitis C, human immunodeficiency virus, herpes, Dengue, Japanese encephalitis virus, coronaviruses, NDv, infectious bursal disease virus and influenza viruses (10-16).

Consequently, the improved survival and tissue health in the infected birds highlight the efficient and protective action of MNLE. This came supported with the previous finding of Helmy (16) about anti-NDv activity of MNLE in Vero cells and chicken embryo. Moreover, the ameriolative action of MNLE may be attributed to ability of different the neem tree parts in the inhibition of inflammatory factors such as nitric oxide and tumor necrosis factor (17), and improving the expression of the immune mediators such as interleukins, interferon, and cytokines in mucosal surfaces (30-32), high nutritional value of neem leaves in the broiler chicken that used as feed components (33) due to its high protein content and an abundance of minerals and vitamins such as calcium, phosphorus, magnesium, iron, vitamin C, and beta-carotene (8-9).

MNLE alleviated not only the disease picture of ND but also virus shedding at 3, 5, and 7 dpc from oropharyngeal swabs of the infected chicks and viral isolation at 7 dpc from the trachea, spleen and cecal tonsils, which were significantly reduced due to the ability of phytochemicals in neem leaves to stop essential steps in the life cycle of the ND virus, like getting into cells and making copies of themselves (7, 34-35). This is correlated with our findings from the high amount of total phenolic and flavonoids in MNLE with high potential scavenging and antioxidant activities. These came in agreement with previous reports about the effectiveness against NDv of the *Azadirachta indica* extracts and other herbal extracts such as *Synadenium glaucescens*, *Artemisia annul L.*, and *Moringa Oleifera* (29, 36-37). Similarly, Helmy (16) found the methanol extract of neem leaves at 3- 4 µg /ml and 4 µg /egg completely inhibiting the NDv replication in VERO cells and chicken embryos, respectively, with the absence of cytotoxicity. The presence of phytochemicals in herbal as phenolic, anthroquinones, flavonoids, and tannins can protect the body tissues and improve survival rates, in addition, to being responsible for its antiviral activity and potential for treating a wide range of diseases (6, 38-40). In conclusion, the pathological changes caused by a Newcastle disease infection could be mitigated by MNLE, which would also reduce NDv shedding and infectivity. This plant is used in traditional medicine and may provide a model for developing novel antivirals.

## Conclusion

In the current study, the neem leaf had a high extraction yield and quantity of total phenolic and flavonoids, as well as potential scavenging and antioxidant capabilities. Consequently, the methanolic neem leaf extract was used to control the ND infection at a dose of 500 and 1000 µg/kg BW which resulted in a significant reduction in morbidity and mortality rates, as well as the macroscopic and microscopic lesion scoring of all examined organs, when compared to the infected untreated group. Moreover, Positive benefits of herbal treatment for experimentally ND-infected chicken were evidenced by a reduction of viral RNA concentrations in oropharyngeal swabs at 3, 5, and 7 dpc and the infectivity titer of the isolated virus from the trachea, spleen, and cecal

tonsils at 7 dpc. MNLE could counteract tissue damage generated by Newcastle disease virus infection and reduce its shedding and infectivity. Traditional cures like this plant could be a source of inspiring alternative new antivirals.

## Acknowledgments

All authors contributed to conceptualization, methodology, investigation, resources, and editing supervision. Writing original draft and Statistical analysis - Sawsan Sami Elbasuni. All authors have read and agreed to the published version of the manuscript.

The authors declare no conflict of interest

## References

1. Miller PJ, Koch G. Newcastle disease, other avian paramyxoviruses, and pneumovirus infections. In Swayne D, Boulianne M, Logue CM, McDougald LR, Nair V, Suarez D, eds. *Diseases of Poultry*. W Black Pub, 2018; 112–28.
2. OIE. Newcastle Disease. 2.3.14. OIE Manual of Diagnostic Tests and Vaccines for Terrestrial Animals, 2012.
3. Dao TT, Nguyen, PH, Lee, HS, et al. Chalcones as novel influenza A (H1N1) neuraminidase inhibitors from *Glycyrrhiza inflata*. *Bioorg Med Chem Lett* 2011; 21 (1): 294–8.
4. Cattoli GL, Susta C, Brown C. Newcastle disease: A Review of Field Recognition and Current Laboratory Detection Methods. *J Vet Diag Invest*, 2011; 23 (4): 637–6.
5. Miller PJ, Haddas R, Simanov L, et al. Identification of New Sub-Genotypes of Virulent Newcastle Disease Virus with Potential Panzootic Features. *Infect, Gene and Evol* 2015; 29: 216–9.
6. Raza A, Muhammad F, Bashir S, et al. Antiviral and Immune Boosting Activities of Different Medicinal Plants against Newcastle Disease Virus in Poultry. *W Poult Sci J*. 2015; 71(3): 523–32.
7. Alzohairy MA. Therapeutics Role of *Azadirachta indica* (Neem) and Their Active Constituents in Diseases Prevention and Treatment. *Evid Compl and Alter Med*, 2016; 2016–27.
8. Ali A. *Textbook of Pharmacognosy*, Publication and Information Directorate, New Delhi, India, 1993.
9. Biswas KI, Chattopadhyay R, Banerjee K, et al. Biological Activities and Medicinal Properties of *Neem* (*Azadirachta Indica*). *Cur Sci* 2002; 82(11): 1336–45.
10. Tiwari V, Darmani NA, Yue BYJT, et al. In-vitro Antiviral Activity of *Neem* (*Azadirachta indica* L.) Bark Extract against Herpes Simplex Virus Type-1 Infection, *Phyto Res* 2010; 24(8):1132–40.
11. Ashfaq UA, Jalil A, Qamar MT. Antiviral Phytochemicals Identification from *Azadirachta indica* Leaves against HCV NS3 Protease: an In Silico Approach. *Nat Prod Res* 2016; 30(16):1866–9.
12. Dwivedi VD, Tripathi IP, Mishra SK. In Silico Evaluation of Inhibitory Potential of Triterpenoids from *Azadirachta Indica* against Therapeutic Target of Dengue Virus, NS2B-NS3 Protease. *J Vect Dis* 2016; 53(2):156–72.
13. Dwivedi VD, Singh A, El-Kafraway SA, et al. Mechanistic Insights into The Japanese Encephalitis Virus RNA DependintoRNA Polymerase Protein Inhibition by Bioflavonoids from *Azadirachta indica*. *Sci Rep* 2021;11(1): 1–13.
14. Pooladanda V, Thatikonda S, Godugu C. The Current Understanding and Potential Therapeutic Options to Combat COVID-19. *Fut J Pharm Sci* 2021; 7 (72):11.
15. Ather A, Costigliola V. Treatment and Control of Covid-19 (Corona Virus Disease 2019) by Non-Invasive Non-Drug Therapy in Combination Anti-Influenza an (Oseltamivir (rx) Tamiflu) Drug- Novel Case Report. *Inter J L Sci* 2020; 6(2):2480–6.
16. Helmy WA, Abd-Alla HI, Amer, H. Chemical Composition and 'In vitro' Antiviral Activity of *Azadirachta indica* A. Juss (Neem) Leaves and Fruits against Newcastle Disease Virus and Infectious Bursal Disease. *Virus* 2007.
17. Kim WH, Song HO, Jin CM, et al. The Methanol Extract of *Azadirachta indica* A. Juss Leaf Protects Mice against Lethal Endotoxemia and Sepsis. *Biom. and Therap* 2012; 20 (1):96–103.
18. Aziza SPA, Hossain MA. Study on Total Phenolic and Antioxidant Activity of Leaves Crude Extracts of *Annona squamosa* Traditionally Used for the Treatment of Cancerous Tumours, *Asi Pac J. Trop Dis* 2015; 5 (1).
19. El-Hadary AE, Ramadan MF. Antioxidant Traits and Protective Impact of *Moringa oleifera* Leaf Extract against Diclofenac Sodium-Induced Liver Toxicity in Rats. *J. F Bio* 2019; 43(2):2704.
20. Desouky AI. Trials of Isolation and Identification of New Sub-Genotypes of Virulent Newcastle Disease Virus from Broiler Chicken in Qa-

lyubia Governorate. Master thesis of Vet Med, Benha University 2020.

21. Hussein EA, Hair-Bejo M, Adamu L, et al. Scoring System for Lesions Induced by Different Strains of Newcastle Disease Virus in Chicken. *Vet Med Int* 2018; 2018.

22. Wise MG, Suarez DL, Seal BS, et al. Development of a Real-Time Reverse-Transcription PCR for Detection of Newcastle disease virus RNA in Clinical Samples. *J. Cl Micro* 2004; 42(1): 329–67.

23. Reed LJ, Muench H. A Simple Method of Estimating Fifty percent Endpoint. *Am J Trop Med* 1938; 27: 493–7.

24. Marks F, Rodenbusch C, Okino C, et al. Targeted Survey of Newcastle Disease Virus in Backyard Poultry Flocks Located in Wintering Site for Migratory Birds from Southern Brazil. *P Vet Med* 2014; 116–26.

25. Bello MB, Yusoff K, Ideris A, et al. Diagnostic and Vaccination Approaches for Newcastle Disease Virus in Poultry: The Current and Emerging Perspectives. *Biomed Res Int* 2018; 2018.

26. Wakamatsu N, King DJ, Kapczynski DR, et al., Experimental Pathogenesis for Chickens, Turkeys, and Pigeons of Exotic Newcastle Disease Virus from an Outbreak in California during 2002–2003. *Vet Path* 2006; 43:925–33.

27. Okoye JOA, Agu AO, Chineme CN, et al. Pathological Characterization in Chickens of a Velogenic Newcastle Disease Virus Isolated from Guinea Fowl. *R d' méd vét trop* 2000; 53(4).

28. Susta L, Miller PJ, Afonso CL, et al. Clinicopathological Characterization in Poultry of Three Strains of Newcastle Disease Virus Isolated from Recent Outbreaks. *Vet Path* 2011; 48(2):349–409.

29. Tolba H, Elmaaty AA, Farag GK, et al. Immunological Effect of Moringa Oleifera Leaf Extract on Vaccinated and Non-Vaccinated Hubbard Chickens Experimentally Infected with Newcastle Disease Virus. *S J Bio Sci* 2022; 29(1): 420–6.

30. Ben-Shabat S, Yarmolinsky L, Porat D, et al. Antiviral Effect of Phytochemicals from Medicinal Plants: Applications and Drug Delivery Strat-

egies. *Drug Del Trans Res* 2020; 10 (2):354–67.

31. Subapriya R, Nagini S. Medicinal Properties of Neem Leaves: A review, *Cur Med Chem Anti Ag* 2005; 5(2): 149–56.

32. Davis L, Kuttan G. Suppressive Effect of Cyclophosphamide-Induced Toxicity by Withania somnifera Extract in Mice. *J. Ethnopharm* 1998; 62(3): 209–14.

33. Sadekar RD, Kolte AY, Barmase BS, et al. Immune Potentiating Effects of Azadirachta indica (Neem) Dry Leaves Powder in Broilers, Naturally Infected with IBD virus. *Ind J Exp Bio* 1998; 36(11): 1151–4.

34. Badam L, Joshi SP, Bedekar SS. In vitro' Antiviral Activity of Neem (Azadirachta indica. A. Juss) Leaf Extract against Group B Coxsackie Viruses, *J Com Dis* 1999; 31(2): 79–90.

35. Parida MM, Upadhyay C, Pandya G, et al. Inhibitory Potential of Neem (Azadirachta indica Juss) Leaves on Dengue Virus Type-2. Replication. *J Ethnopharm* 2002; 79(2): 273–8.

36. Goebel SJ, Taylor J, Barr BC, et al., Isolation of Avian Paramyxovirus 1 from a Patient with a Lethal Case of Pneumonia. *J Viro* 2007; 81:12709–33.

37. Liu Y, Yan G, Chen G, et al. Efficacy Trials of Crude Extraction from Artemisia Annu L. against Newcastle Disease Virus In vivo in Xinjiang. *Mod Appl Sci* 2009; 3(5): 176–8.

38. Malar TRJ, Jeba J, Vijayaraghavan P, et al. In-vitro Phytochemical and Pharmacological bio-efficacy Studies on Azadirachta indica A. Juss and Melia azedarach Linn for Anticancer Activity, *S J Bio Sci* 2020; 27(2): 682–8.

39. Nandhakumar E, Indumathi P. In vitro Antioxidant Activities of Methanol and Aqueous Extract of Annona Squamosal Fruit Pulp. *J Acup Mer Stud* 2013; 6:142–50.

40. Ruchi T, Verma A K, Chakraborty S, et al. Neem (Azadirachta indica) and its Potential for Safeguarding Health of Animals and Humans: A Rev. *J. BioSci.* 2014; 14: 110–23.