

ARTHROSCOPIC TREATMENT OF AN INCOMPLETE AVULSION FRACTURE OF THE SUPRAGLENOID TUBEROSITY IN A DOG

Antonello Bufalari^{1*}, Giulia Moretti¹, Alessia Proni², Valentina De Monte¹, Antonio Di Meo¹

¹Department of Veterinary Medicine, University of Perugia, Via San Costanzo, 4, Perugia (PG), 06126; ²Veterinary Clinic H24 Firenze, Via senese, 249/b Galluzzo (FI), 50124, Italy

*Corresponding author, E-mail: antonello.bufalari@unipg.it

Summary: A thirteen month-old, female English Setter was referred for a non-weight-bearing lameness of the left thoracic limb. Clinical and radiographic findings were consistent with a left supraglenoid tubercle incomplete fracture. The anamnesis reported a lameness arising 5 months earlier after a traumatic injury. After a period of conservative treatment, lameness had not resolved. Clinical examination revealed grade 3/5 lameness and pain on manipulation of the shoulder joint. Medio-lateral radiographic projection revealed a distinct irregular radiolucent line between the greater tubercle and the glenoid.

An arthroscopic examination was performed and a careful and complete debridement and revitalisation of the subchondral bone was performed. As reported in the literature, a rigid compressive internal fixation is usually indicated when a joint is involved, but, in the case presented herein, the dog's history and young age led us to believe that a minimally-invasive treatment should be satisfactory.

Radiographic controls were carried out at 3, 6, 16 and 19 months following the surgical procedure, revealing a complete fusion and regular margins of the supraglenoid tubercle. Clinical signs of lameness resolved definitively at 3 months after surgical treatment.

To the best of the Authors' knowledge, cases of incomplete avulsion fracture of the supraglenoid tuberosity managed with arthroscopic surgery have not been described.

Key words: supraglenoid tubercle; shoulder; fracture; arthroscopic treatment; dog

Introduction

Traumatic injury of the shoulder joint is a common cause of foreleg lameness in dogs. In domestic carnivores, the supraglenoid tuberosity has its own centre of ossification and fuses with the remainder of the scapula towards five to six months of age (1).

In most cases (2), ligamentous or tendinous injuries, fractures or luxations are implicated. Avulsion fractures of the supraglenoid tuberosity usually occur in juvenile animals, as a result of a

faulty landing following a jump (3). Typically, this involves a marked hyperflexion of the shoulder, which considerably increases the traction exerted by the *biceps brachii* muscle (4).

To the best of the Authors' knowledge, cases of incomplete avulsion fracture of the supraglenoid tuberosity managed with arthroscopic surgery have not been described.

Case description

A thirteen month-old, female English Setter weighing 15.5 kg was referred to the Veterinary Teaching Hospital of the University of Perugia with a non-weight-bearing lameness of the left forelimb.

The owner reported a lameness arising 5 months earlier, probably as a result of a traumatic event. For three months, the dog was kept at rest and showed an acceptable improvement. However, after a few weeks of normal activity, the lameness recurred. Clinical examination findings pointed out reluctance to walk, grade 3/5 lameness based on the Quinn scale (5). At rest, the dog maintained the shoulder and the carpus in a flexed position. Inspection revealed a little swollen area over the cranio-lateral aspect of the left scapulo-humeral joint, which was painful on palpation. There was some mild muscle reduction of the left forelimb that was judged to have been caused by disuse. Moreover, extension and flexion of the shoulder also caused the dog pain and movements of abduction. Neurological examination was within normal limits.

Findings of the orthopaedic examination were compatible with a traumatic injury of the proximal part of the bicipital tendon and/or its insertion. Other articular disease like an extra-articular scapular or humeral injury could not be clinically excluded.

After sedation with dexmedetomidine 4 µg/kg IV (Dexdomitor®: Orion Corporation Orion Pharma, Espoo, Finland), a radiographic study (mediolateral and caudocranial projections) was carried out. Mediolateral radiographic views of the affected limb showed an abnormal shape of the distal part of the supraglenoid tuberosity; this area showed also a radiolucent and irregular linear defect surrounded by small irregular radiolucent flaws and mild sclerosis. The trabecular pattern of the bone was not detectable (Figure 1). Since a traumatic event was implicated, a suspect of incomplete avulsion fracture was made.

To complete the diagnostic procedure and, if necessary, with the potential of following-up with minimally invasive treatment, an arthroscopic examination was performed to assess the fracture site as well as the other intra-articular structures (6). After premedication with acepromazine 10 µg/kg (Prequillan®, Fatro Spa, Bologna, Italy) and metadone 0.2 mg/kg IV (Eptadone®, Molteni Spa, Firenze, Italy), general anaesthesia was induced with 3 mg/kg of propofol (Proposure®, Merial Italia Spa, Milano, Italy.), and maintained after intubation with a mixture of isoflurane (Isoflo; Esteve Spa, Milano, Italy) and oxygen (50-100 ml/kg/min) via a circle breathing circuit with spontaneous ventilation.

The left forelimb was prepared for aseptic surgery: trichotomy and aseptic disinfection was

performed at wide margin around the supraglenoid tubercle. The dog had an arthroscopic examination of shoulder using an arthroscope (2.7mm, 30° oblique arthroscope, Small Joint Arthroscope: Karl Storz GmbH & Co. KG, Tuttlingen, Germany) connected to a video camera and image-recording device. A standard lateral shoulder portal (7) allowed evaluation of all major structures. Inspection of the middle and caudal compartment of the joint revealed severe synovitis. Overall, arthroscopy ruled out any other associated injury, particularly capsular tears. In the cranial area, an intra-articular fracture of the supraglenoid process was found. The avulsion fracture had an extension from the gleno-humeral ligament to the biceps brachii insertion site. A circular fissure was clearly visible with partial cracks in the central portion of the fissure. Using an hook probe and also through the manipulation of the scapular joint during direct visualization of the fracture line it was possible to evaluate the degree of the mobility of the tuberosity. This portion did not showed to be mobile during these procedures. At the point of fracture, two fragments of non-vital subchondral bone and of yellow colour (diameter 2x1mm) were removed. In the fissure line, deep debridement and revitalisation of the subchondral bone was performed using bone graspers, double-spoon forceps, hand burr and mastoid curette (Karl Storz GmbH & Co. KG, Tuttlingen, Germany). alternately (Figure 2).

At the end of surgery, the arthroscope and surgical instruments were removed and the joint was flushed copiously with lactated Ringer's solution(8). After recovery from anaesthesia, 0.01 mg/kg of buprenorphine (Temgesic®, RB Pharmaceuticals Limited, Milano, Italy) and 0.2 mg/kg of meloxicam (Metacam®, Boehringer Ingelheim, Milano, Italy) were administered subcutaneously to provide postoperative analgesia.

The two fragments of non-vital subchondral bone and of yellow colour removed during arthroscopy were immediately fixed in 10 % neutral buffered formalin and routinely embedded in paraffin. The samples were sectioned and stained with Haematoxylin & Eosin for histopathological assessment that revealed cartilaginous tissue with regular cartilaginous lacunae and chondrocytes in different stages of maturation in irregular arrangement, associate with diffuse and small foci of fibrous tissue. Several and marginal areas of the samples showed focal activation of

normal endochondral ossification and focal mild hemorrhages. Due to the histopathological findings, characterized mostly by cartilaginous activation process, and the clinical data, the diagnosis of suspect reparative process was done (Figure 3).

One day later, the dog was discharged and the owner was directed to follow a medical therapy based on the administration of FANS for 7 days and to keep the animal at rest for 3 months.

Radiographic controls were carried out at 3, 6, 16 and 19 months following the surgical procedure

(Figure 4). At 3 months after surgery, at the physical examination, there were no abnormalities such as lameness or pain after manipulation of the affected limb. At the last control (19 months after arthroscopic surgery), clinical examination showed similar results to the previous controls. Indeed, a significant improvement of the bone shape and radiopacity of the bone was noted; however, a small radiolucent defect of the surface of the cranial glenoid cavity was identified (Figure 5).

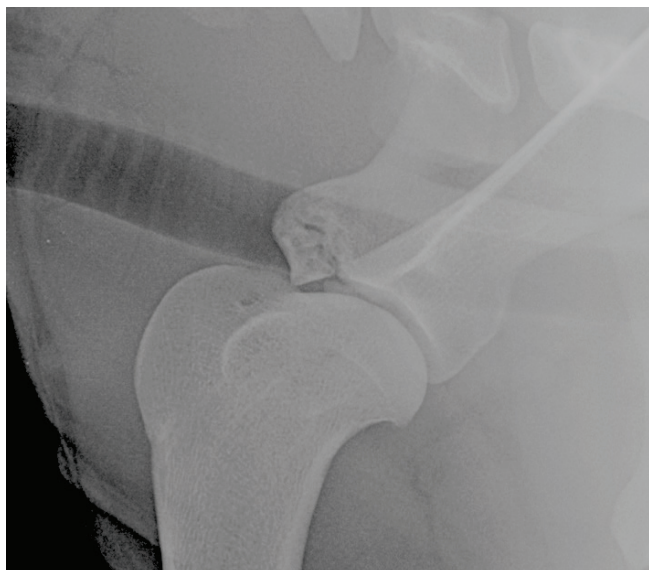

Figure 1: Mediolateral radiographic projection of the left shoulder

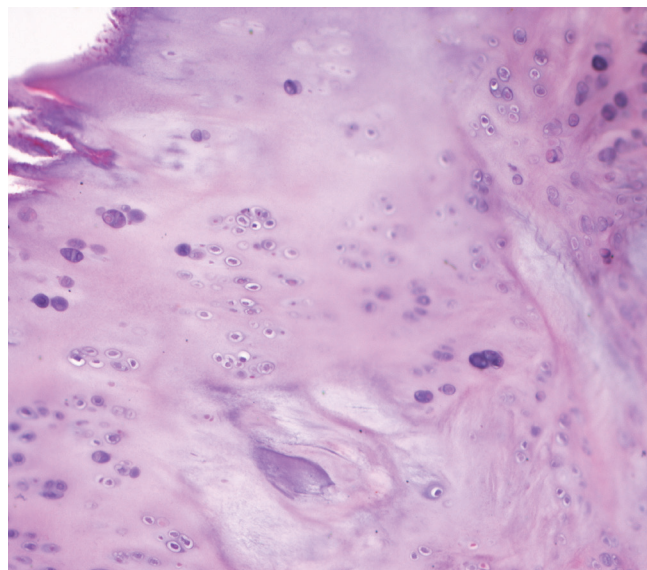


Figure 3: Histological section of subchondral bone, 10 x, Haematoxylin & Eosin. Cartilaginous tissue with regular cartilaginous lacunae and chondrocytes in different stages of maturation associated to area of normal endochondral ossification

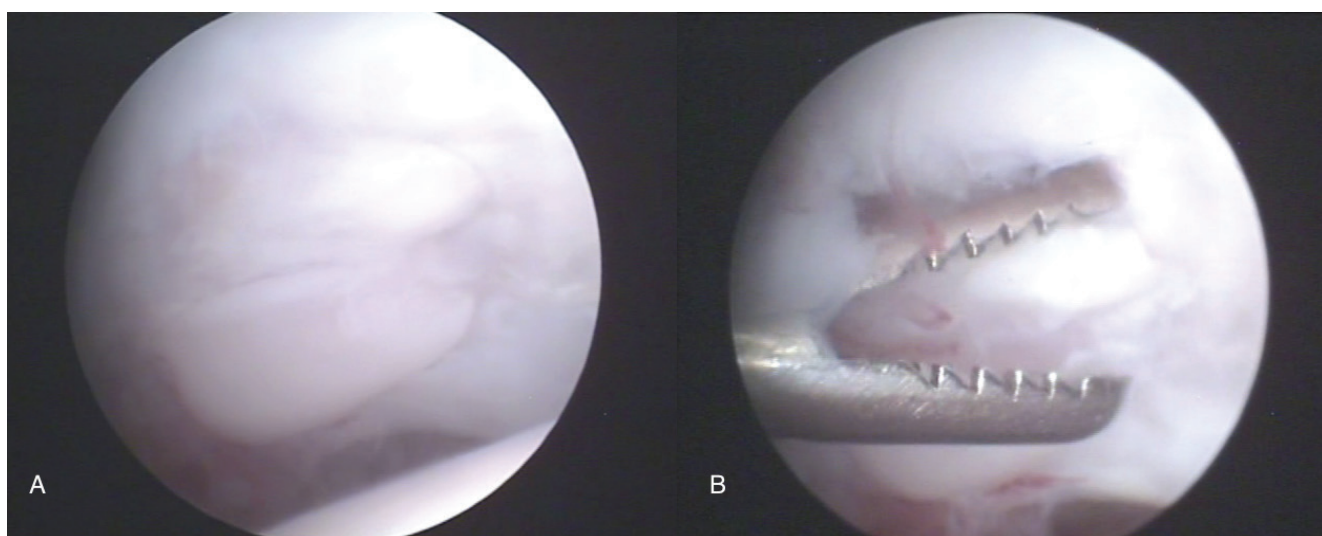


Figure 2: (A) Arthroscopic view of the avascular bone fragment. (B) Removal of the bone fragment by grasping forceps

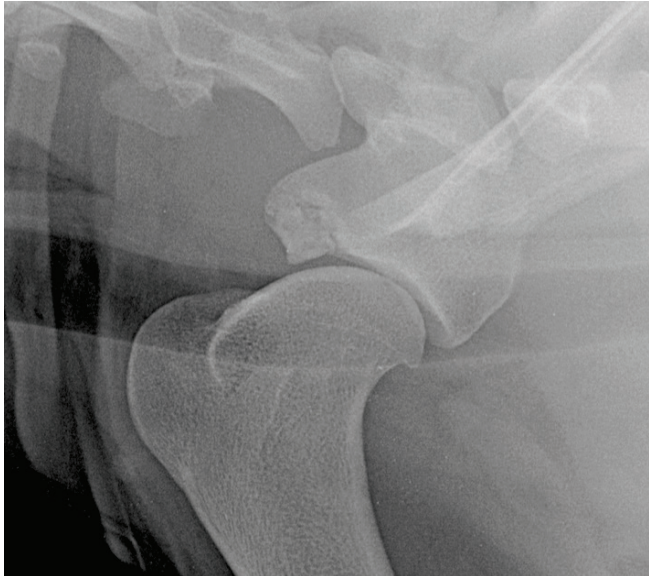


Figure 4: Mediolateral radiographic projection of the left shoulder 16 months after arthroscopic treatment

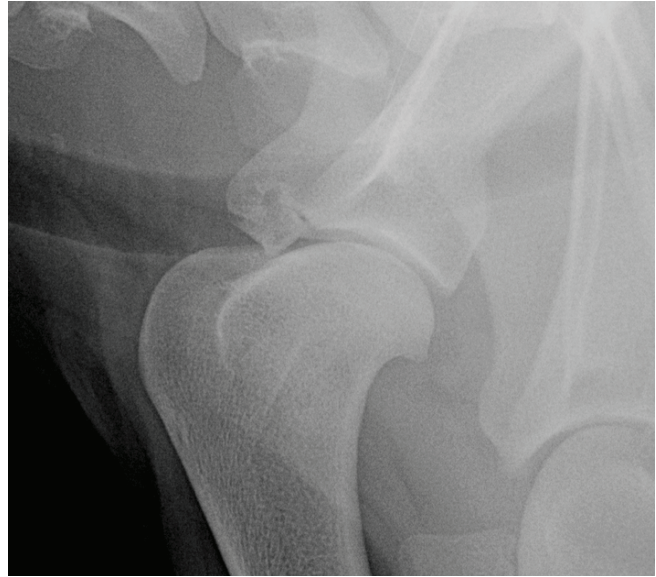


Figure 5: Mediolateral radiographic projection of the left shoulder at last control 19 months after arthroscopic treatment

Discussion

Supraglenoid tuberosity is the site of origin of the *biceps brachii* muscle and develops as a separate centre of ossification, normally fusing on to the scapula by 5 months of age. Although fracture is uncommon (9), it mostly occurs as a result of direct force exerted on the shoulder region; on the contrary, the avulsion fracture of supraglenoid tuberosity appears to be due to an indirect force (10). In this report, the aetiopathogenesis of the described lesion was unknown. Non-weight-bearing lameness and an abnormal limb posture, as observed in this dog, are classically described as an avulsion fracture of the supraglenoid tuberosity (11). As described in literature (4) the lameness is caused by pain due to instability of the supraglenoid tuberosity that caused micro-movements at the level of the fracture line. Moreover, the pull due to the biceps brachii tendon during flexion of the shoulder has created continue micro-fractures that could have affect the healing process. This kind of injury is detectable by shoulder radiograph. In this case, the radiographic study showed an incomplete avulsion fracture of the supraglenoid tuberosity of left forelimb. Furthermore, it is necessary to address that at the first visit, x-ray exams were not carried out by the first Practitioner, which does not exclude the remote possibility that the fracture was originally complete. However, the Authors

assume that the fracture was probably incomplete from the beginning because the physiologic pull of the *biceps brachii* tendon would create too large a gap that would not allow bony fusion. Moreover, the first radiographic exams showed a bone profile that was quite linear and homogeneous, which suggests an originally incomplete injury. When a joint is involved, surgery is indicated and the prognosis is more guarded, as described by Johnston (12). The prognosis for articular fracture is related to the alignment and rigidity of internal fixation (1). Some authors recommend a rigid compressive internal fixation, although this technique may compromise growth in the case of physeal injuries (13, 14). In the case presented here, the conservative treatment did not lead to a complete resolution of the injury. A minimally invasive arthroscopic treatment, instead of an internal fixation technique, was chosen despite the articular involvement. Management of articular cartilage lesions is based on the idea that healing, through the formation of fibrocartilage, is promoted when the lesion is exposed to blood that contains mesenchymal stem cell precursors (7, 15). Several methods are used. Abrasion arthroplasty involves the uniform removal of subchondral bone until bleeding is achieved. Here, we created several microcracks in the subchondral bone plate to allow bleeding at the lesion surface (7, 15, 16).

Another aetiopathogenetic hypothesis to consider is chondrodysplasia. In the literature, a

case in which an English setter showed bilateral abnormal ossification of the supraglenoid tubercles has been described (17). The ossification disorder involved the proximal and distal segments of the supraglenoid tubercle, as well as the cranial articular surface of the glenoid cavity. In that report, diagnosis was consistent with osteochondrosis or focal chondrodysplasia. In this case, the Authors did not consider this lesion as an abnormal ossification of the supraglenoid tubercle, since the lesion was monolateral and secondary to an injury (18). Moreover, radiographic aspect of the observed lesion showed a substantial difference compared to those showed by De Simone (17). A good conservative therapeutic strategy to obtain an immobilization of the forelimb, is the application of a Velpeau bandage. In the Authors' opinion, the complete immobilization of the limb for a long period could cause a certain degree of muscle atrophy that might reduce or slow down the full functional recovery of the limb. Therefore for this case, in the postoperative period, we considered more appropriate keeping the dog at rest in a limited cage both in height and in width without the application of any bandage, in order to maintain a physiological loading of the limb and also to avoid a severe amyotrophy. Accordingly to our clinical experience, the previous conservative treatment followed by the dog did not bring any significant improvement, while arthroscopic surgery was effective to ameliorate the clinical condition for the incomplete avulsion fracture of the supraglenoid tuberosity in this dog.

References

1. Brinker WO, Piermattei DL, Flo GL. Handbook of small animal orthopedics and fracture treatment. 2nd ed. Philadelphia: Saunders WB, 1990.
2. Innes JF, Brown G. Rupture of the biceps brachii tendon sheath in two dogs. *J Small Anim Pract* 2004; 45: 25–8.
3. Leijnen M, Steenvoorde P, Da Costa A, et al. Isolated apophyseal avulsion of the coracoid process: case report and review of literature. *Acta Orthop Belg* 2009; 75: 262–4.
4. Deneuche AJ, Viguiet E. Reduction and stabilisation of a supraglenoid tuberosity avulsion under arthroscopic guidance in a dog. *J Small Anim Pract* 2002; 43: 308–11.
5. Quinn MM, Keuler NS, Lu Y, Faria MLE, Muir P, Markel MD. Evaluation of agreement between numerical rating scales, visual analogue scoring scales, and force plate gait analysis in dogs. *Vet Surg* 2007; 36: 360–7.
6. Åkerblom S, Sjöström L. Evaluation of clinical, radiographical and cytological findings compared to arthroscopic finding in shoulder joint lameness in the dog. *Vet Comp Orthop Traumatol* 2007; 20: 136–41.
7. Martini FM, Pinna S, Del Bue M. A simplified technique for diagnostic and surgical arthroscopy of the shoulder joint in the dog. *J Small Anim Pract* 2002; 43: 7–11.
8. Beale BS, Hulse DA, Schulz KS, Whitney WO. Small animal arthroscopy. Philadelphia: Saunders, 2003: 50–79.
9. Denny HR, Butterworth SJ. A guide to canine and feline orthopaedic surgery. 4th ed. Oxford: Blackwell Science, 2000: 303–40.
10. Binnington AG. Fractures of the scapular tuberosity. *Can Vet J* 1974; 15: 152–5.
11. Hulse DA, Johnson AL. Scapular fractures: management of specific fracture. In: Fossum TW ed. Small animal surgery. St Louis: Elsevier Mosby, 1997: 778–4.
12. Johnston SA. Articular fractures of the scapula in the dog: a clinical retrospective study of 26 cases. *J Am Anim Hosp Assoc* 1993; 29: 157–64.
13. Eaton - Wells RS. Injuries of traction growth plates. In: Bojrab MJ, ed. Disease mechanisms in small animal surgery. Philadelphia: Lea & Febiger 1993: 1042–7.
14. Roy R, Dee J. Management of articular fractures, sprains and strains. In: Houlton J, Collinson R, eds. Manual of small animal arthrology. Gloucester : BSAVA, 1994: 55–61.
15. Lanny L, Johnson MD. Arthroscopic abrasion arthroplasty historical and pathologic perspective: present status. *Arthroscopy* 1986; 2: 54–69.
16. Olivieri M, Ciliberto E, Hulse DA, Vezzoni A, Ingravalle F, Peirone B. Arthroscopic treatment of osteochondritis dissecans of the shoulder in 126 dogs. *Vet Comp Orthop Traumatol* 2007; 20: 65–9.
17. De Simone A, Gernone F, Ricciardi M. Imaging diagnosis—bilateral abnormal ossification of the supraglenoid tubercle and cranial glenoid cavity in an English Setter. *Vet Radiol Ultrasound* 2013; 54: 159–63.
18. De Bakker E, Samoy Y, Gielen I, Van Ryssen B. Medial humeral epicondylar lesions in the canine elbow. *Vet Comp Orthop Traumatol* 2011; 1: 9–17.

ARTROSKOPSKO ZDRAVLJENJE NEPOPOLNEGA AVULZIJSKEGA ZLOMA NADPONVIČNE GRBICE PRI PSU

A. Bufalari, G. Moretti, A. Proni, V. De Monte, A. Di Meo

Povzetek: Trinajstmesečna samička angleškega setra je bila napotena na pregled zaradi nenasilnega šepanja leve sprednje okončine. Ugotovitve kliničnega pregleda in rentgenskega slikanja so kazale na nepopolni zlom leve nadponvične grbice. Anamneza je poročala o šepanju, ki izhaja iz travmatske poškodbe, povzročene 5 mesecev pred pregledom. Po obdobju konservativnega zdravljenja šepanje ni prenehalo. Klinični pregled je pokazal oceno šepanja 3/5 in bolečino pri manipulaciji ramenskega sklepa. Mediolateralna rentgenska projekcija je pokazala izrazito radiolucenčno linijo med večjo grbico in sklepom. Opravljena je bila artroskopska preiskava, skrbno in popolno odstranjevanje odmrlega tkiva ter revitalizacija subhondralnega dela kosti. Kot poročajo v literaturi, je po navadi v takšnih primerih potrebna toga čvrsta notranja fiksacija, če je v poškodbo vključen sklep. Vendar bi v tem primeru glede na zgodovino psičke in njeno mladost morale zadostovati minimalno invazivno zdravljenje. Rentgenske kontrole so bile opravljene 3, 6, 16 in 19 mesecev po kirurškem posegu in so razkrile popolno zlitje in ravne robove nadponvične grbice. Klinični znaki šepanja so dokončno izveneli v 3 mesecih po kirurškem zdravljenju. Po vednosti avtorjev v literaturi še niso bili opisani primeri nepopolnega avulzijskega zloma nadponvične grbice, ki bi bili odpravljeni z artroskopsko operacijo.

Ključne besede: nadponvična grbica; pleče; zlom; artroskopsko zdravljenje; pes