

AVIAN CORONAVIRUS IN EGYPT: EPIDEMIOLOGICAL ACUITIES AND PATHOGENICITY IN COMMERCIAL BROILER CHICKENS

Ali M. Mahmoud^{1,2}, Reham M. ElBakrey¹, Shima M.G. Mansour^{3*}, Amal A.M. Eid^{1*}

¹Department of Avian and Rabbit Medicine, Faculty of Veterinary Medicine, Zagazig University, Zagazig, Sharkia 44511, ²Veterinary Medicine Directorate, Mansoura, Dakahlia, ³Department of Virology, Faculty of Veterinary Medicine, Zagazig University, Zagazig, Sharkia 44511, Egypt

*Corresponding author, E-mail: amalaetidvet@gmail.com, shimaagalal@gmail.com

Mailing address: Department of Avian and Rabbit Medicine, Faculty of Veterinary Medicine, Zagazig University, Zagazig, Sharkia 44511, Egypt

Abstract: Infectious bronchitis virus (IBV), a gamma coronavirus, is responsible for a highly contagious disease in chickens resulting in substantial economic losses to the poultry industry around the world. The emergence of new types of IBVs is considered one of the major concerns regarding to IB. A preliminary diagnosis of IB was made based on the flock history and the characteristic pathologic findings. In the current study, we investigated the outbreaks of respiratory signs and diarrhea in broiler chickens (n=77) between 2014 and 2018. Upon necropsy, the affected chickens showed tracheal and kidney lesions, suggestive of IBV. The IBV was detected in 33 farms using real-time reverse transcription-PCR, targeting the nucleocapsid gene. Investigation of IBV among vaccinated chickens would considerably ameliorate the present immunization programs and support the development of more effective vaccines. The IBV was detected in vaccinated birds (45.8%). The virus was isolated in fertile chicken eggs, which revealed embryonic mortality (20-40%) within 5-7 days after the 3rd passage, small embryos or dwarfing up to 30.2% versus non-inoculated ones. Virus pathogenicity was determined experimentally in 7-day-old broiler chickens inoculated oculo-nasally with 10⁴ median embryo infective dose. The infected birds experienced severe respiratory signs, diarrhea and tracheal and renal lesions. The virus displayed a wide range of tissue tropism, particularly in the trachea, lungs and kidneys, and was shed via the respiratory tract and cloaca. The results emphasized the significance of conducting a comprehensive surveillance of IBV infections among chicken flocks in Egypt and provide significant insights into the virulence properties of IBV. Further studies of nucleotide sequence analysis of circulating IBV strains and evaluation of vaccine efficacy are needed.

Key words: IBV; RT-PCR; pathogenicity; clinical scoring; histopathology; nephropathogenic strain

Introduction

Coronaviruses (CoVs) infect a variety of animals including chickens (*Gallus gallus*) and can induce respiratory, enteric, neurological and hepatic diseases of variable severities. Avian coronaviruses (AvCoVs) belong to genus *gammacoronavirus*, subfamily *Coronavirinae*, and contain infectious bronchitis virus (IBV) and other bird coronaviruses. The most prominent representative of

gammacoronavirus genus is IBV which is a highly transmissible viral pathogen of chickens and incurs considerable economic losses to the poultry industry (1). The IBV has the ability to cause respiratory disease in all ages of chickens. Its morbidity is 100% with low mortality but in some nephropathogenic strains can be >50% or when complicated with other pathogens such as *Escherichia coli*. Besides, the reproductive tract can be

affected in layers and breeders resulting in decrease in egg quality and production rate (2).

Generally, mammalian coronaviruses occur as only one or a few different serotypes within a species; however AvCoV has many different serotypes, which make it unique among all other CoVs. IBVs, along with other members of coronaviruses, have unique viral replication machinery which allows the recombination in their structural proteins with a high frequency [3]. Their predilection for variations based on the high rates of mutation and recombination results in tissue tropism, pathogenicity, and adaptation to immunologically and/or genetically resistant hosts (3, 4, 5).

IBV is an enveloped, positive single-stranded RNA virus, consists of three main structural proteins: the spike (S1 and S2), the membrane (M), the nucleocapsid (N) glycoproteins. The S1 gene has a highly variable nucleotide sequence, making it prone to mutation and emergence of new variant strains. Since the first isolation of IBV in Massachusetts in the 1930s, the virus has spread worldwide and evolving rapidly. For many years, the only recognized serotype of IBV was the Mass serotype, until Jungherr et al. identified a new IBV type using the virus neutralization test in 1956 (6).

In Egypt, IB was firstly identified in 1954 (7). Later, high disease prevalence was proven by several records (8-10). At various chicken farms, IBV strains similar to the Massachusetts D3128, D-08880, D274 and 4/91 genotypes have been identified (10-13). In 2001, the Egyptian variant strain (Egypt/Beni-Suef/01) was isolated from different poultry farms (8). Additionally, seven IBV isolates with low nucleotide similarity to the vaccinal strains were documented in the Damietta province (14). During 2010-2015, the circulating IBV strains in twelve Egyptian provinces were clustered into two variant groups on the basis of S1 nucleotide sequence analysis (15). Lately, the Egyptian variant strains were clustered in the GI-23 lineage based on S1 gene analysis (16).

The use of live-attenuated and inactivated IBV vaccines, as well as adequate biosecurity, are the mainstays of IB control. Despite systematic IBV vaccination, IB outbreaks are common in the field due to the presence of different serotypes along with the emergence of multiple subtypes, which are caused by point mutations, deletions, insertions, or RNA recombination of the S1

genes (17, 18). Antigenic variants of IBV complicate the diagnosis process; accordingly, distinction is necessary for proper control and using suitable preventive measures. The abovementioned criteria make continual global surveillance and identification of IBV types considerably important. In the view of increasing epidemiological importance of IBV strains, the first objective of this study was to investigate the situation of IBV among broiler chickens in four Egyptian provinces during 2014-2018. The second objective was to assess the pathogenicity of field IBV isolate in broiler chicks.

Material and methods

Sampling

The study was conducted in commercial chicken broiler flocks exhibiting severe respiratory distress, diarrhea and high mortality. It involved different localities within 4 provinces; Sharkia (n=22), Dakahlia (n=47), Qalubia (n=5) and Damietta (n=3), Egypt, based on convenience and approachability of chicken farms during December 2014- January 2018. Birds came from 77 chicken flocks selected in the investigation areas, representing large-scale broiler farms containing 3,000-30,000 birds housed in a closed system and small-scale farms containing 200-2000 birds. The analysis was achieved based on the clinical pictures of the disease, breed, and age, source of the chicks, vaccination programs, observed signs and mortalities. Chickens of different ages ranging from 17-90 days were admitted to the Department of Avian and Rabbit Medicine, Faculty of Veterinary Medicine, Zagazig University, Egypt for necropsy. Tissue samples including trachea, lungs and kidney were collected. A suspension of tissue homogenates (1:10 w/v) was prepared with sterile phosphate-buffered saline (PBS) then centrifuged at 3000 rpm for 10 min. Pen/Strep (Lonza) was added to the supernatant fluids with a final concentration of 1000 IU penicillin and 1000µg streptomycin per ml (19).

RNA extraction, real-time RT-PCR

Total RNA was extracted from tissue using a total RNA extraction Kit (Applied Biotechnology Co. Ltd, Egypt) in accordance to the manufacturer's instructions. Non-infected birds and reference IBV vaccinal strain were included as negative

and positive controls, respectively. The extracted RNA was subjected to one-step Taqman real-time RT-PCR using AgPath™ One-Step RT-PCR kit (Applied Biosystems) for detection of IBV using primer pair and probe targeting N gene (20).

Viral isolation

The real-time RT-PCR positive IBV specimens (trachea and kidneys) were inoculated into 10-day old embryonated chicken eggs (ECEs) via allantoic cavity route following the OIE recommendations (19). A volume of 200 µl from each tissue homogenate was inoculated into the allantoic cavity of fertile eggs (5 eggs for each sample). Additionally, five fertile eggs were kept non-inoculated as negative control. The ECEs were incubated at 37°C for up to 7 days with daily monitoring for embryonic mortality. Eggs showed non-specific embryonic death within the first 24 h post-inoculation were removed. The dead and live embryos at 7 days post-inoculation were chilled at 4°C overnight and then examined. The allantoic fluids were collected and further passaged for a maximum of five passages. Correspondingly, they were tested by rapid hemagglutination (HA) assay using 10% washed chicken RBCs. The extracted RNA from the harvested allantoic fluids were subjected to RT-PCR for confirmatory detection of IBV. Additionally, the positive HA allantoic fluids were screened for the presence of hemagglutinating viruses using the primers and probe targeting the conserved region of M gene of NDV (21) and influenza A virus (22). After that, the samples with amplified M segments were further subtyped for HA gene using specific primers and probes for H5 (23), H7 (24) and H9 (25) subtypes of AIV.

Pathogenicity study

To elucidate the characteristics of IBV isolate from kidney tissue, pathogenicity in chicks was investigated. Twenty-five commercial 1-day-old Cobb chickens (Dakahlia Poultry Company, Egypt) were reared in experimental units under strict hygienic conditions. Blood and tissue specimens were collected from five chicks for detection of anti-IBV antibodies and IBV, respectively. Serologically negative chickens were randomly divided into 2 groups 10 birds for each. The first

group was assigned for determination of pathogenicity at 7-day old and inoculated oculonasal with 0.1 ml allantoic fluid contains 10^4 EID₅₀. Additionally, the other ten sham-inoculated chicks were housed separately from the infected birds as a negative control group. The birds were monitored at least twice daily for a total of 21 days. The clinical signs were recorded according to the clinical scoring method described in Wang & Huang (26). Gross pathologic lesions in the trachea and kidney along with pathogenicity index were computed based on the criteria presented by Wang & Huang (26). Oropharyngeal and cloacal swabs were collected from infected and control chickens at 1, 3, 5, 7, 10 and 14 days post-infection (dpi) for virus detection. Chickens were euthanized at 7, 14 and 21 dpi, necropsied and the organs were sampled for PM lesions, virus detection and histopathology. The real-time RT-PCR was done for IBV detection in the collected tissues and swabs. The experimental studies were undertaken in strict accordance with the use of animals for experiments as permitted by the IACUC Institutional Animal Care and Use Committee, Zagazig University, Egypt (approval No.: ZU-IACUC/2/F/72/2021).

Histopathological examination

The tissue specimens including trachea, lungs, kidney, proventriculus and intestine were fixed in 10% neutral buffered formalin for 48 hours. The tissues were routinely processed and embedded in paraffin. The paraffin blocks were sectioned and stained with hematoxylin and eosin (H&E) to be microscopically examined for any significant findings (27).

Enzyme linked immuosorbent assay (ELISA)

Sera were collected from IBV-infected and sham-inoculated chickens at 7, 14, 21 dpi. Commercially available IBV antibody test kit (IDEXX Europe B.V. The Netherlands) was used for the detection of specific antibodies against IBV following the manufacturer's instructions. Serum samples were tested in duplicates. Optical density values were read at specific wave length, 450 nm, using ELISA Micro-plate reader (Sunrise, TECAN, Austria).

Statistical analysis

The detection rate of IBV infection was determined from the proportion of positive to the total number of tested samples by real-time RT-PCR. The bivariate logistic regression analysis was used to analyze the difference in IBV detection, in relation to different study variables (SPSS Inc., Chicago, IL, USA). Crude Odds Ratios (COR) and their 95% confidence interval (95% CI) were also noticed. Statistical differences were considered significant at P values < 0.05. The results of serum antibody titer were expressed as the means \pm S.D. (standard deviation).

Results*Clinical and postmortem findings*

The clinical signs of the investigated birds included ruffled feathers, sinusitis, lacrimation, anorexia, huddling together and whitish diarrhea. Respiratory signs were recorded in 98.7% of examined flocks and included sneezing, coughing, nasal discharges, rales, and gasping.

Greenish diarrhea was noticed in 27.3% of flocks (21/77). The recorded mortality rates were (1-33.3%). On autopsy, severe tracheitis, bronchitis and congestion of lungs were the main common gross lesions in the examined chickens. Caseated plugs (84.4%; 65/77) were recorded at the tracheal bifurcation.

Table 1: Mortalities and clinical findings of broiler chickens naturally infected with IBV in 4 Egyptian provinces during 2014-2018

No	Mortality Rates (%)	Clinical signs		Gross lesions				Positive IBV tissue	Detected virus (s)
		Respiratory	Diarrhea	Tracheitis/ Bronchitis	Caseated plugs	Nephrosis	Nephritis		
1	6	+	Whitish	+	+	+	-	Kidney	IBV
2	8	+	Whitish	+	-	+	-	Kidney	IBV
3	9	+	Whitish	+	-	+	-	Kidney	IBV
4	12	+	Whitish	+	+	-	+	Kidney	IBV
5	6.5	+	Whitish	+	+	+	-	Kidney	IBV
6	16	+	Whitish	+	-	+	-	Kidney	IBV
7	8	+	Whitish	+	-	+	-	Kidney	IBV
8	10	+	Whitish	+	+	-	+	Kidney	IBV
9	20	-	Whitish	-	-	+	+	Kidney	IBV, IBDV
10	4	+	Whitish	+	-	+	+	Kidney	IBV
11	12	+	Whitish	+	-	+	+	Kidney	IBV, IBDV
12	5	+	Whitish	+	+	-	+	Kidney	IBV
13	7	+	Whitish	+	+	-	+	Trachea/kidney	IBV
14	7	+	Whitish	+	+	+	-	Trachea/kidney	IBV
15	10	+	Whitish	+	+	+	-	Trachea/kidney	IBV, H9AIV
16	11	+	Whitish	+	+	+	-	Trachea/kidney	IBV
17	7	+	Greenish	+	+	+	-	Trachea	IBV, NDV
18	5	+	Whitish	+	+	-	+	Trachea	IBV
19	9	+	Whitish	+	+	+	-	Trachea	IBV
20	10	+	Whitish	+	+	+	-	Trachea	IBV
21	5	+	Whitish	+	+	+	-	Trachea	IBV, H9AIV
22	6	+	Whitish	+	+	+	-	Trachea/kidney	IBV
23	22	+	Whitish	+	+	+	-	Trachea/kidney	IBV
24	21	+	Whitish	+	+	+	-	Trachea/kidney	IBV
25	6	+	Whitish	+	-	-	+	Kidney	IBV
26	2	+	Whitish	+	-	+	+	Kidney	IBV
27	2.5	+	Whitish	+	+	+	-	Trachea	IBV, H9AIV
28	17	+	Whitish	+	+	+	+	Trachea/kidney	IBV, H9AIV
29	18	+	Whitish	+	-	+	+	Trachea/kidney	IBV
30	2.2	+	Whitish	+	-	+	-	Kidney	IBV
31	19	+	Whitish	+	-	+	+	Kidney	IBV
32	11	+	Whitish	+	+	+	+	Trachea/kidney	IBV
33	4.8	+	Whitish	+	+	+	-	Trachea	IBV

+ mean present, - mean absent

Table 2: Molecular detection of IBV in broiler chicken flocks in 4 Egyptian provinces during 2014-2018

Variable	No. of flock	No. of Positive samples (%)	Odds ratio	95% CI, OR	P-value
Province					
Sharkia	22	10 (45.5%)	RF		
Dakahlia	47	20 (42.6%)	0.88	0.32-2.4	0.821
Qalubia	5	2 (40%)	0.80	0.11-5.7	0.825
Damietta	3	1 (33.3%)	0.60	0.04-7.6	0.694
Breed					
Cobb	37	18 (48.6%)	RF		
Sasso	24	9 (37.5%)	0.63	0.22-1.8	0.393
Avian 48	6	5 (83.3%)	5.2	0.56-49.6	0.146
White	4	1 (25%)	0.35	0.03-3.7	0.384
Ross	1	0	0		1
Native	5	0	0		0.999
Flock size					
≤ 5,000	22	12 (54.5%)	RF		
> 5,000- ≤ 10,000	30	7 (23.3%)	0.25	0.07-0.83	0.024*
> 10,000	25	14 (56%)	1.06	0.33-3.35	0.920
Age (day)					
≤4 weeks	37	20 (54.1%)	RF		
>4 weeks	40	13 (32.5%)	0.40	0.16-1.03	0.058
Vaccination status					
Vaccinated	59	27 (45.8%)	RF		
Non-vaccinated	18	6 (33.3%)	0.59	0.19-1.79	0.354
Total	77	33 (42.9%)			

*Statistically significant association ($P < 0.05$).

OR = odd ratio; CI = confidence interval of OR; RF = reference factor

Swollen, pale kidneys with a visible tubules structure, and ureters distended with urates were recurrently detected among 57.1% (44/77) of examined birds. Also, nephritis was detected in 32 flocks (41.6%). Moreover, enteritis; enlarged and ulcerated cecal tonsils were seen in some flocks (18.2%; 14/77). On the other hand, fibrinous pericarditis, perihepatitis, and air sacculitis (52%; 40/77) were recorded.

Molecular detection of IBV and other viruses

On the basis of the N gene-directed RT-PCR, 42.9% of examined specimens (33 out of 77 broiler chicken farms) were positive for IBV (95% CI: 31.6% to 54.6%). Additional analysis indicated that the IBV was detected in 17 out of 77 (22.1%) tracheal specimens, and 26 out of 77 (33.8%) kidney samples. On the other hand, screening of HA positive allantoic fluids for NDV and AIV showed 4 flocks were positive for AIV and were identified as low pathogenic avian influenza virus subtype H9. There were no H5 or H7 subtypes found. The NDV was detected in one flock. Three flocks exhibited bursal lesions

were subjected to molecular identification (28) revealed two positive IBDV flocks (Table 1). Additionally, the detection rate of IBV in chickens was reconnoitered according to 5 factors; province, breed, flock size, age and vaccination status (Table 2). The rate of IBV detection was ranged from 33.3% to 45.5% in investigated provinces. Among 6 chicken breeds examined, the Avian 48 chicken breed was the most infected one (83.3%) and no, IBV detection in native and Ross breed. Infection rates varied between 33.3-45.8% in non-vaccinated and vaccinated flocks, and reached to 56% in intensive fowl farms with flock size >10,000 birds.

Viral isolation on ECEs

The IBV was isolated from positive tracheal and kidney tissues. After three to five passages, embryos showed decrease in weight and length with a percentage of 14.2%-30.2% in comparison to non-inoculated embryos. The embryonic deaths reached to 20-40% within 5-7 days post inoculation upon successive embryo passages. Five HA positive allantoic fluids were detected.

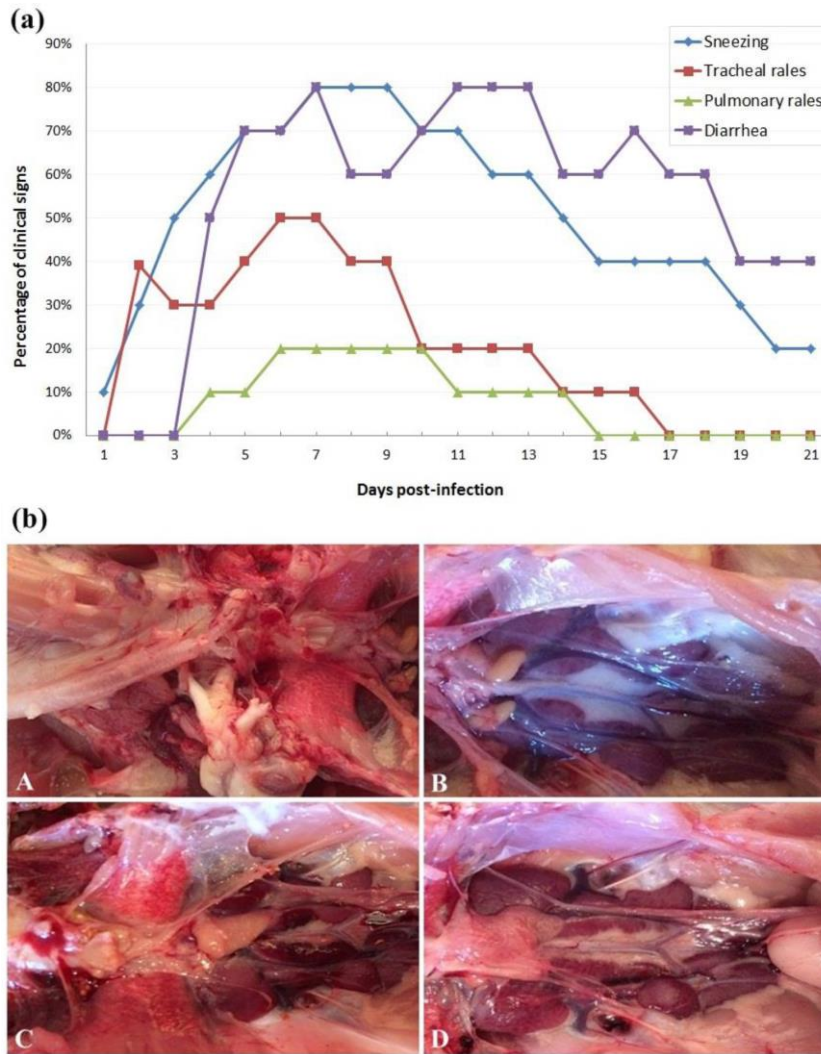


Figure 1: Clinical findings (Upper panel (a) and gross lesions (Lower panel (b) of 7-day-old broiler chickens experimentally infected with IBV. **(A)** Trachea and lungs from non-infected control chicken. **(B)** Kidney tissue from non-infected control chicken. **(C)** Lung of infected chickens showing congestion at 14 dpi. **(D)** Pale swollen cranial and caudal lobes of kidney tissues from infected chickens at 21 dpi

Experimental infection (pathogenicity test)

Clinical signs and gross pathological findings

Clinical observation of infected chicks revealed at first, respiratory signs in form of sneezing and tracheal rales as early as 2 dpi (3/10 birds). At 4 dpi, pulmonary rales (10%), gasping, the birds huddling together (40%) and watery diarrhea (5/10) were recorded. Five days post infection, brownish wet droppings (n=3) were observed. Respiratory clinical signs and diarrhea were observed in the inoculated chicks and were intense and more severe until 7 dpi (Figure 1a, Upper panel). The most noticeable respiratory signs were sneezing, gasping, cough, difficulty in breathing, tracheal and pulmonary rales, with high scores were reported at 7 dpi. Nasal discharge and watery eyes were also observed. Within two weeks of observation, the symptoms were less severe, 80% of chickens had diarrhea

and individual birds showed mild respiratory signs. The chickens in the sham-inoculated control group were alert and active during the experiment.

At necropsy, the sham-inoculated control chickens showed no lesions (Figure 1A, B). The infected and control chicks that were euthanized at 7, 14 and 21 dpi were examined for the macroscopic lesions. The gross lesions were slight tracheitis, air sacculitis, congested lungs (Figure 1C) and swollen kidneys that mainly progressed. Pale, swollen kidneys with a visible tubules structure, and/or ureters distended with urates were observed (Figure 1D). The intestinal tracts were bloated, filled with yellowish content. Based on tracheal and kidney lesions scoring, the IBV strain used in pathogenicity study was classified according to pathogenicity index (index=14) to intermediate virulence.

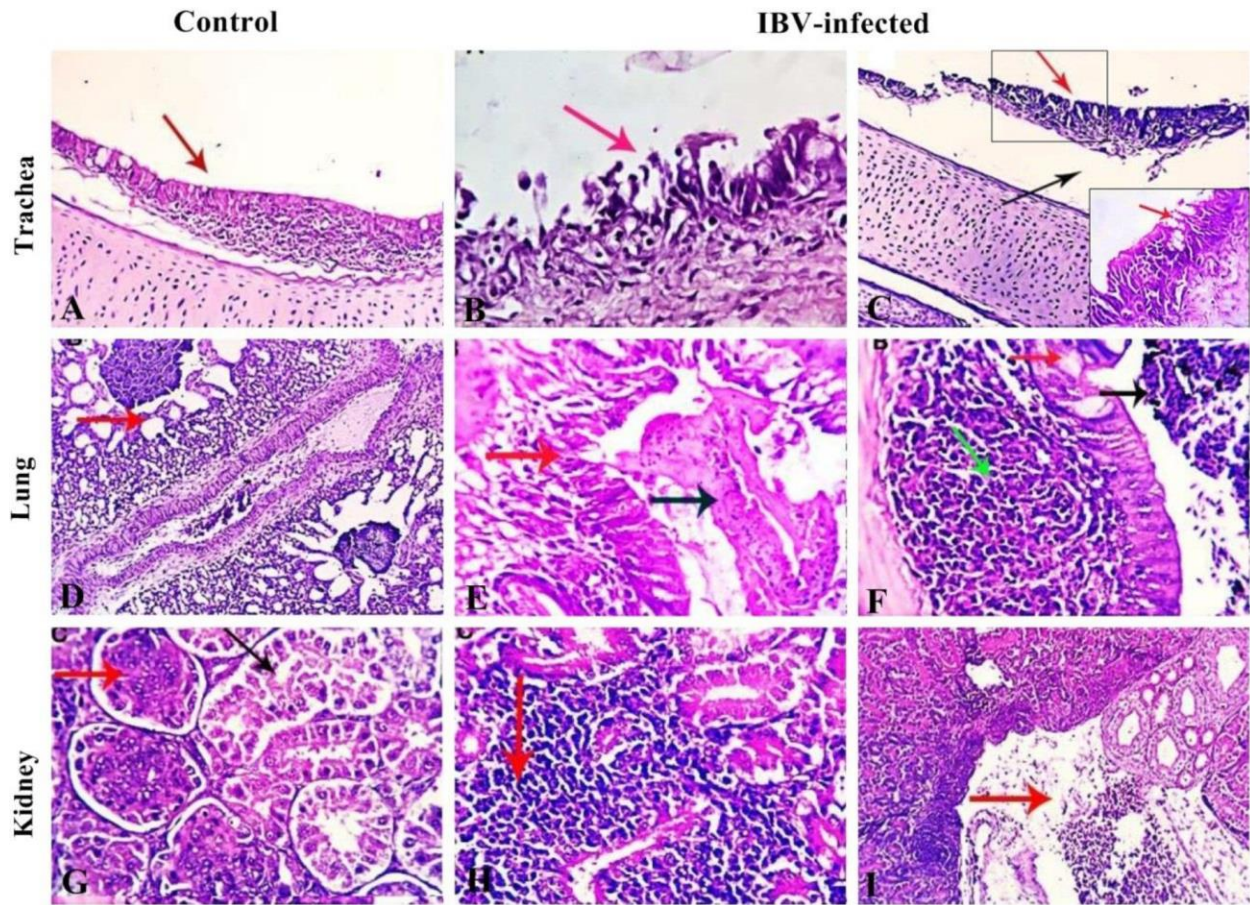


Figure 2: Histopathological findings of 7-day-old broiler chickens experimentally infected with IBV (Stain H&E). **(A)** Trachea of non-infected control chickens showing normal ciliated tracheal epithelial and normal mucosal and sub-mucosal structures (red arrow), X200. **(B)** Trachea of infected chickens at 7 dpi showing epithelial erosion, necrosis, sloughing and round cells infiltration (red arrow) X400. **(C)** Trachea (14 dpi) showing tracheal sub-mucosal round cells infiltration (red arrow) and edema (black arrow) X200, Square (X400). **(D)** The pulmonary tissue of control chickens appears with normal histomorphological structures (red arrow), X200. **(E)** Primary bronchus (14 dpi) showing acute and subacute lymphocytic bronchitis with mucosal epithelial erosion (red arrow), round cells infiltration and accumulation of exudative fluid in the lumen (black arrow), X400. **(F)** The pulmonary tissue (14 dpi) showing characteristic lymphocytic bronchitis (arrows) X400. **(G)** The kidney of control chicken shows normal tubular and glomerular structures (black and red arrows) X400. **(H)** Kidney (14 dpi) shows marked interstitial lymphocytic nephritis (red arrow) X400. **(I)** Kidney shows marked vascular dilation (congestion), interstitial edema, hemorrhages and multifocal round cells aggregation, X200

Histopathological examination

Microscopic examination of the control birds showed a normal histological structure of the trachea, lungs, and kidneys along the period of experiment (Figure 2A, D, G). The severity of the microscopic lesions varied among the different examined organs alongside days post infection. The tracheal lesions were observed in birds between 7 and 14 dpi, including variable degrees of epithelial erosion and necrosis of the ciliated cells in the trachea, and sub-mucosal lymphocytic infiltration, round cells infiltration and edema (Figure 2B, C)

At the end of observation (21 dpi), the recovery of the tracheal mucosa was exhibited, although the inflammatory cell infiltration was still observed. The main bronchi revealed acute and subacute lymphocytic bronchitis with mucosal epithelial erosion, round cells infiltration and accumulation of exudative fluid in the lumen (Figure 2E). Moderate to severe inflammatory cell infiltration was found in the lungs (Figure 2F).

Whereas, the microscopic examination of kidney sections revealed tubular epithelial degenerative necrotic and apoptotic changes, focal glo-

merular shrinkage, sometimes glomerular mesangial cells proliferation and occasional tubular epithelial regeneration (Figure 2G). Marked interstitial lymphocytic aggregations and glomerular mesangial cells proliferation with marked vascular dilation (congestion), interstitial edema, hemorrhages and multifocal round cells aggregation were observed at 21dpi (Figure 2I). The proventriculus showed mucosal epithelial squamous metaplasia and round cells infiltration, interlobular edema and lymphoid follicular aggregations. The intestine showed focal mucosal and submucosal round cells infiltration, villous epithelial erosion and denudation beside goblet cells metaplasia (Data not shown).

Detection of IBV in swabs and tissue samples

The IBV detection was checked in swabs and tissue samples collected at 7, 14 and 21 dpi. The determined viral shedding from the respiratory and digestive tract was detected using Taqman real-time RT-PCR and was 100% of collected swabs from infected chickens at 7 dpi. Moreover, the virus was found in the tissues of the trachea and lungs at 7 dpi, and the kidney at 14 and 21 dpi. The proportion of IBV-positive samples in infected chickens was 37%. No viral RNA was detected in any tissues or swabs from the control group.

Antibody response to IBV using ELISA

The mean antibody titers against IB (Anti-IBV) in the sera collected from infected and control chicks on days 7, 14 and 21 dpi was estimated by ELISA. In the infected chickens, sera were negative at 7 dpi then titers were increased at 14 and 21 dpi (mean \pm standard deviation) with a value of 796.3 ± 69.71609 and 1963 ± 522.9426 , respectively. Serum samples of the sham-inoculated chicks were free from anti-IBV on the entire dpi.

Discussion

IBV is one of the most serious infections resulting in economic losses in the poultry industry around the world. Immunoprophylaxis is the key approach to manage IBV infections since the virus has varying tissue tropism and pathogenic features (29). The disease result was mostly linked to respiratory symptoms and/or watery diarrhea, according to field observations. Effective vaccinations must be used to combat IBV infections.

Though, frequent viral mutations and recombination, which can boost the virus's virulence and modify its antigenicity, may have a negative impact on vaccination. Although, the IBV vaccines are directed to various bird categories, several disease outbreaks are still reported worldwide (30, 31).

This study was conducted to explore the present situation of IBV infection among broiler chicken flocks in 4 Egyptian provinces. For this purpose, IBV identification was achieved by investigation of 77 broiler chicken flocks that exhibited general signs of illness, respiratory manifestations and diarrhea. Mild to severe respiratory signs were observed including conjunctivitis accompanied with lacrimation, sneezing, coughing, gasping, and rales with mortality rate ranged from 1-33.3%. The clinical course depends on other variables including environmental and management factors (32) or the presence of concomitant pathogens (33). Even if the IBV infection is mild and transient, it is usually followed by secondary bacterial infection, such as *Escherichia coli* (34, 35). As a result, infection with these isolates in commercial flocks would make chicks susceptible to bacterial infection, leading to convoluted morbidity and increased mortality. Post mortem examination generally revealed mild to severe congestion of tracheal mucosa and small areas of pneumonia. Mucous or caseated material was frequently seen in the trachea and bronchi of some flocks. Fibrinous pericarditis, perihepatitis and airsacculitis were also observed. Some flocks showed pale or congested and enlarged kidneys with prominent tubules with deposition of urates. Slight to moderate distention of the ureters with urates were also seen. The clinical signs and gross lesions were comparable to those described by many authors (8, 36) and suggested IBV infection. We hypothesize that possible co-infections with other pathogens, such as NDV, low pathogenic AIV and bacteria that may play a critical role in exacerbating the clinical picture of IBV infections in broiler chickens; such findings have been previously reported (37).

Along with the pathologic findings, the real-time RT-PCR results confirmed the presence of IBV in 33/77 farms (42.9%). Nearly similar detection rate (41%) was reported in previous study (38). A higher percentage of IBV infection (69.2%)

was recorded by Awad et al (14). Variants of IBV have been identified in a variety of locations, and they are having an economic impact on poultry production worldwide (39). Antigenic variation, which results in a lower amount of cross protection between strains, is a key roadblock to developing an effective vaccine. In the present study, the IBV was detected in 45.8% of vaccinated broiler flocks. The IBV detection in the most of field outbreaks poses a serious challenge for controlling the disease in Egypt. In consequence, further biosecurity measures should be strictly enjoined. However, a provincial vaccination strategy based on particular native strains could be adapted plus the general vaccines based on the ubiquitous genotypes. The diagnosis of IBV-associated disease in these flocks proposes that i) the currently used IBV vaccines are not effectual for protection against the circulating viral strains in Egypt, ii) the applied vaccination regimen was insufficient to give appropriate protection, or iii) birds are exposed to additional respiratory pathogens, by stress during vaccination, decreasing the immunity. These speculations need to be defined in upcoming studies. Interestingly, lower percentage of IBV was reported in non-vaccinated flocks (33.3%), conversely with the high detection rate (79.4%) recorded by (14). Concerning the virus isolation in ECEs, the IBV isolates produced variably low embryonic death and/or dwarfing after 3-5 serial blind passages, which were consistent with the previous findings described in other studies [36, 40]. The findings of increasing embryo mortalities upon further passage could indicate that the IBV isolates are field viruses since, they were not embryo adapted (41).

IBV infections are primarily characterized by respiratory manifestations and variable degrees of renal dysfunction (42, 43). Even in nephropathogenic strains, the virus initially replicates in the tracheal cells, inducing histological lesions identical to those caused by the respiratory strains. Mild respiratory signs followed by depression, diarrhea and sever weight loss is the characteristic feature of the nephritic form of IB (44). So far, only a few pathogenicity investigations for the IBV GI-23 genotype have been published (45)]. Infection of one-day-old SPF chickens with the Var2 IBV-Eg/1212B-2012 strain resulted in severe kidney and tracheal lesions as well as significant mortality

rate (50%) according to Zanaty et al. (15). Sequentially, another IBV GI-23 strain (IS/885/00-like), produced tracheal and urinary lesions, and cystic oviduct, but mortality was 2.2% (46). Both studies used one-day-old SPF chickens and broilers and demonstrated that the GI-23 strains have a wide range of pathogenicity. In the present study, the virulence properties of IBV isolate with renal lesions was assessed using 7-day-old broiler chickens. The obtained results demonstrated that the strain under investigation has a moderate pathogenicity and causes disease. The respiratory signs and histopathological lesions were more severe at 7 dpi. Although the histopathological alterations detected in kidneys were more severe, the virus showed mostly respiratory and renal tissue tropism. It is known that the young chickens have the most severe clinical response to IBV, and severity decreases with the age (47, 48). This fact explains the elevated mortality found in 1-day-old chickens experimentally infected with Egypt/F/03 in comparison to mortality pattern in the original flock (25-day-old chickens). On the other hand, no mortality was recorded in the pathogenicity study conducted here; however, this isolate induce 6% mortality in original chicken flock. Though, it should be emphasized that the virulence of IBV strains depends on many factors like virus dose, route of inoculation, age, and breed of the birds or the properties of the strain itself. Additionally, the infection resulted in lower body weight gains. Curiously, the IBV infection in experimental chickens resulted in brownish diarrhea, similarly, dark-brown wet droppings were observed in one-day-old SPF chickens experimentally infected with IBV (GI-23 strain gammaCoV/Ck/Poland/G052/2016).

The presented findings of the *in-vivo* study may be surprising to field veterinarians as they frequently see an acute form of disease in 4–6-week-old chickens with substantial mortality (45). As indicated, virus was shed via the respiratory and digestive tracts. The gross and microscopical changes caused by the IBV strain were comparable to those described in a report on nephropathogenic IBV strains (49), hence the isolate was classified as a nephropathogenic IBV strain. The strain Egypt\F\03 is a nephrogenic IBV, as evidenced by the presence of acute interstitial nephritis on days 5 and 7 post infection (13). The microscopic

findings of the renal tubules resembled those recorded with nephrogenic IBV strains (50, 51). The microscopic observations in tracheal sections were consistent with those described by Toro et al. (47) and Purcell et al. (50) including: loss of cilia, degenerative alterations of the tracheal mucosa, uneven loss of epithelium, desquamation of the sloughed epithelium in the tracheal lumen and focal to diffuse lymphocytic infiltration.

IBV is characterized by high genetic and antigenic diversity (45). This heterogeneity is critical, particularly in connection with the application of an effective immunoprophylaxis program, as vaccination does not always provide adequate cross-protection beyond the virus lineage. The availability of various commercial vaccines gives the possibility to select vaccine strains based on antigenic similarity to the circulating strains in the field. Therefore, from a practical point of view, genotyping of field IBV strains is crucial for the implementation of an efficient immunoprophylaxis. As a result, more research is needed to assess the protective efficacy of different vaccination regimens against field IBV strains circulating in Egypt. Here, antibodies against IBV were measured using an ELISA assay in experimentally infected chickens at 7, 14 and 21 dpi. On day 14 post-infection, ELISA showed moderate levels of IBV antibody, followed by high levels of anti-IBV on day 21 post-infection. After exhibiting particular clinical signs, these findings confirm that infected chickens seroconverted against IBV. Indeed, Ghadakchi et al. (52) demonstrated that ELISA could be used to detect IBV antibodies in a consistent, reproducible, and sensitive manner. Using ELISA, Emikpe et al. (53) assessed the prevalence of IBV antibodies in southwestern Nigeria. Their finding showed that IBV antibody titer increased following virus infection.

In conclusion, the outcome of this study provides a link between the epidemiologic and pathogenic perception, allowing for the development of effective IBV control strategies. IBV continues to circulate among poultry farms in Egypt despite vaccination efforts. The high rate of IBV detection (45.8%) in vaccinated chicken flocks, suggests that the virus is still evolving and mutate in Egypt. Vaccines currently in use are insufficient to deliver adequate protection against IBV strains. Besides, the study affords significant insights into

the virulence properties of IBV strain isolated from a clinical case of IB in broiler chickens. Further epidemiological national surveillance with nucleotide sequencing is required to clarify the mechanism of emergence of variant strains and their biological properties, including pathogenicity, together with developing appropriate vaccines from endemic IBV strains. Review and improvement of the currently applied IBV vaccine regimens should be considered.

References

1. Cavanagh D, Gelb J. Infectious bronchitis. In: Saif YM, ed. *Diseases of Poultry*, 12th ed. Ames: Wiley-Blackwell Publishing, 2008: 101-20.
2. Jackwood MW. Review of infectious bronchitis virus around the world. *Avian Dis* 2012; 56(4):634-41.
3. Woo PCY, Lau SKP, Lam CSF, et al. Comparative analysis of complete genome sequences of three avian coronaviruses reveals a novel group 3c coronavirus. *J Virol* 2009; 83: 908-17.
4. Jackwood MW, de Wit S. Infectious bronchitis. In: Swayne DE, ed. *Disease of poultry*, 13th ed. USA: John Wiley & Sons, Inc, 2017:139-59.
5. Ma T, Xu L, Ren M, et al. Novel genotype of infectious bronchitis virus isolated in China. *Vet Microbiol* 2019; 230: 178-86.
6. Jungherr EI, Chomiak TW, Luginbuh RE. Immunologic differences in strains of infectious bronchitis virus. In: the 60th Annual Meeting. U.S.: Livestock Sanitary Association 1956: 203-9.
7. Ahmed HN. Incidence and treatment of some infectious viral respiratory diseases of poultry in Egypt. Ph.D. Thesis, University of Cairo, Cairo, Egypt, 1954.
8. Abdel-Moneim AS, Madbouly HM, Gelb JR, Ladman BS. Isolation and identification of Egypt/Beni-Seuf/01 a novel genotype of infectious bronchitis virus. *Vet Med J Giza* 2002; 50: 1065-78.
9. Ahmed AA. Infekiose bronchitis des huhnes in Aegypten. *Berl. Munch. Tierarztl. Wschr* 1964; 77: 481-4.
10. Sheble A, Sabry MZ, Davelaar FG, et al. Present status of infectious bronchitis in Egypt. *J Egypt Vet Med Assoc* 1986; 46: 393-411.
11. El-Kady MF. Studies on the epidemiology and means of control of infectious bronchitis disease in chickens in Egypt. PhD Thesis, Faculty of Veterinary Medicine, Cairo University, Egypt, 1989.
12. Sultan HA, Tantawi L, Youseif AI, Ahmed AAS. Uroli-thiathis in white commercial egg laying chickens associated with an infectious bronchitis virus. In: the 6th Sci Conf Egyp Vet Poult Assoc 2004: 155-69.

13. Abdel-Moneim AS, El-Kady MF, Ladman BS, Gelb J Jr. S1 gene sequence analysis of a nephro-pathogenic strain of avian infectious bronchitis virus in Egypt. *Virology J* 2006; 3:78.
14. Awad EM, Arafa AS, El-Deeb AH, El-Sanousi AA. Molecular studies on infectious bronchitis virus isolated from broiler chickens in Damietta Governorate, Egypt. *Zag Vet J* 2016; 44:119-27.
15. Zanaty A, Arafa AS, Hagag N, El-Kady M. Genotyping and pathotyping of diversified strains of infectious bronchitis viruses circulating in Egypt. *World J Virol* 2016; 5:125-34.
16. Valastro V, Holmes EC, Britton P, et al. S1 gene-based phylogeny of infectious bronchitis virus: an attempt to harmonize virus classification. *Infect Genet Evol* 2016; 39: 349-64.
17. Cavanagh D, Davis PJ, Cook J. Infectious bronchitis virus: evidence for recombination within the Massachusetts serotype. *Avian Pathol* 1992; 21:401-8.
18. Jackwood MW, Hall D, Handel A. Molecular evolution and emergence of avian *gammacoronaviruses*. *Infect Genet Evol* 2012; 12(6):1305-11.
19. OIE Terrestrial Manual. Avian infectious bronchitis (Chapter 2.3.2). In: *Manual of Diagnostic Tests and Vaccines for Terrestrial Animals*. [Online]. Available: <http://www.oie.int/standard-setting/terrestrial-manual/access-online/>. 2018; Accessed August 7, 2021.
20. Meir R, Maharat O, Farnushi Y, Simanov L. Development of a real time TaqMan® RT-PCR assay for the detection of infectious bronchitis virus in chickens, and comparison of RT-PCR and virus isolation. *Journal of virological methods* 2010; 163(2): 190-4.
21. Wise MG, Suarez DL, Seal BS, et al. Development of a real-time reverse-transcription PCR for detection of Newcastle disease virus RNA in clinical samples. *J Clin Microbiol* 2004; 42:329-38.
22. Spackman E, Senne DA, Myers TJ, et al. Development of a real-time reverse transcriptase PCR assay for type A influenza virus and the avian H5 and H7 hemagglutinin subtypes. *Journal of clinical microbiology* 2002; 40(9):3256-60.
23. Slomka MJ, Coward VJ, Banks J, et al. Identification of sensitive and specific avian influenza polymerase chain reaction methods through blind ring trials organized in the European Union. *Avian Dis* 2007; 51:227-34.
24. Slomka MJ, Pavlidis T, Coward VJ, et al. Validated Real Time reverse transcriptase PCR methods for the diagnosis and pathotyping of Eurasian H7 avian influenza viruses. *Influenza Other Respir Vi-ruses* 2009; 3:151-64.
25. Ben Shabat M, Meir R, Haddas R, et al. Development of a real-time TaqMan RT-PCR assay for the detection of H9N2 avian influenza viruses. *J Virol Methods* 2010; 168:72-7.
26. Wang CH, Huang YC. Relationship between serotypes and genotypes based on the hypervariable region of the S1 gene of infectious bronchitis virus. *Archives of Virology* 2000; 145(2): 291-300.
27. Suvarna SK, Layton C, Bancroft JD. *Bancroft's Theory and Practice of Histological Techniques*, 7th ed. Churchill Living Stone: Elsevier, England; 2013.
28. Moody A, Sellers S, Bumstead N. Measuring infectious bursal disease virus RNA in blood by multiplex real-time quantitative RT-PCR. *J Virol Methods* 2000; 85:55-64.
29. de Wit JJ, Cook JKA. Spotlight on avian pathology: Infectious bronchitis virus. *Avian Pathol* 2019; 48: 393-5.
30. Roussan DA, Khawaldeh GY, Shaheen IA. Infectious bronchitis virus in Jordanian chickens: seroprevalence and detection. *Can Vet J* 2009; 50(1):77-80.
31. Jordan B. Vaccination against infectious bronchitis virus: a continuous challenge. *Vet Microbiol* 2017; 206:137-43.
32. Raj GD, Jones RC. Infectious bronchitis virus: Immunopathogenesis of infection in the chicken. *Avian Pathol* 1997; 26: 677-706.
33. Jackwood MW, de Wit S. Infectious bronchitis. In: Swayne DE, Boulianne M, Logue CM, McDougald LR, Nair V, Suarez DL, de Wit S, Grimes T, Johnson D, Kromm M, Prajitno TY, Rubinoff I, Zavala G, eds. *Diseases of Poultry*, 14th eds. Hoboken, NJ, USA: John Wiley & Sons. Publishing, 2020: 167-88.
34. Smith, HW, Cook, J KA, Parsell ZE. The experimental infection of chickens with mixtures of infectious bronchitis virus and *Escherichia coli*. *J Gen Virol* 1985; 66:777-86.
35. Vandekerchove D, De Herdt P, Laevens H, Butaye P, Meulemans G, Pasmans F. Significance of interactions between *Escherichia coli* and respiratory pathogens in layer hen flocks suffering from colibacillosis-associated mortality. *Avian Pathol* 2004; 33:298-302.
36. Sediek, MEM. Studies on infectious bronchitis in chickens. M.V.Sc. Thesis, poultry Diseases, Faculty of veterinary Medicine, Alexandria University, Egypt, 2005.
37. Hassan KE, Shany SA, Ali A, et al. Prevalence of avian respiratory viruses in broiler flocks in Egypt. *Poult Sci* 2016; 95(6):1271-80.
38. Lebdah MA, Hegazy AM, Hassan MH, Mohammed ME. Isolation and Molecular Characterization of Infectious Bronchitis Virus from Broiler Chickens, Egypt during 2014 -2016. *Zagazig Veterinary Journal* 2017; 45(1): 11-8.

39. De Wit JJ, Cook JK, van der Heijden HM. Infectious bronchitis virus variants: a review of the history, current situation and control measures. *Avian Pathol* 2011; 40:223-35.
40. Wang HN, Wu QZ, Huang Y, Liu P. Isolation and identification of infectious bronchitis virus from chickens in Sichuan, China. *Avian Dis* 1997; 41: 279-82.
41. Di Fabio J, Rossini LI, Orbell SJ, et al . Characterization of infectious bronchitis viruses isolated from outbreaks of disease in commercial flocks in Brazil. *Avian Diseases* 2000; 582-9.
42. Liu P, Deng G, Guo XQ, et al. Clinicopathology of gout in growing layers induced by avian nephrotrophic strains of infectious bronchitis virus . *Pak Vet J* 2015; 35:345-9.
43. Aslam A, Shahzad MI, Parveen S, et al. Evaluation of antiviral potential of different cholistani plants against infectious bursal disease and infectious bronchitis virus. *Pak Vet J* 2016; 36(3): 302-6.
44. Bayry J, Goudar MS, Nighot PK, et al. Emergence of nephropathic avian infectious bronchitis virus with a novel genotype India. *J Clin Microbiol* 2005; 43: 916-9.
45. Lisowska A, Pikula A, Opolska J, Jasik A, Kycko A, Domańska-Blicharz K. Virulence Properties of GI-23 Infectious Bronchitis Virus Isolated in Poland and Efficacy of Different Vaccination strategies. *Pathogens* 2021; 10(5): 522.
46. Awad F, Chhabra R, Forrester A, et al. Experimental infection of IS/885/00-like infectious bronchitis virus in specific pathogen free and commercial broiler chicks. *Res Vet Sci* 2016; 105: 15-22.
47. Toro H, Kaleta EF, Herbst W, Peixoto P, Frese K. Differences in pathogenicity for young chickens among field isolates of infectious bronchitis virus. *Arch Med Vet Chole*. 1988; 20: 44-50.
48. Mohamed BT. Studies on the prevalence and epidemiology of infectious bronchitis in broiler chickens in El-Minia Governorate. M.Sc. Thesis, Faculty of veterinary Medicine, Cairo University, Beni-Suef branch, Egypt, 2005.
49. Boroomand Z, Asasi K, Mohammadi A. Pathogenesis and tissue distribution of avian infectious bronchitis virus isolate IRFIBV32 (793/B serotype) in experimentally infected broiler chickens. *Sci World J* 2012; 2012.
50. Purcell DA, Tham VL, Surman PG. The histopathology of infectious bronchitis in fowls infected with a nephrotropic T strain of virus. *Aus Vet J* 1976; 52: 85-91.
51. Albassam MA, Winterfield RW, Thacker HL. Comparison of the nephropathogenicity of four strains of infectious bronchitis virus. *Avian Dis* 1986; 30: 468-76.
52. Ghadakchi H, Dadras H, Pourbakhsh SA, Hosseini SMH. Standardization of an Enzyme-Linked Immunosorbent Assay for Detection of Infectious Bronchitis Virus Antibody. *Arch Razi Inst* 2005; 59:75-83.
53. Emikpe BO, Ohore OG, Olujonwo M, Akpavie SO. Prevalence of antibodies to infectious bronchitis virus (IBV) in chickens in southwestern Nigeria. *African Journal of Micro-biology Research* 2010; 4(2): 092-5.