

HERNIORRHAPHY AND SURGICAL OUTCOMES OF DIAPHRAGMATIC HERNIA IN CATS

Mehmet Zeki Yılmaz Deveci^{1*}, Ziya Yurtal¹, Cafer Tayer İşler¹, Sara Büşra Emiroğlu², İbrahim Alakuş¹, Muhammed Enes Altuğ¹

¹Department of Surgery, Clinical Sciences, ²Department of Pharmacology and Toxicology, Faculty of Veterinary Medicine, Hatay Mustafa Kemal University, Box 31040, Hatay, Turkey

*Corresponding author, Email: zekideveci@gmail.com

Abstract: The aim of this study was to evaluate the surgical outcome and mortality of diaphragmatic hernia in cats and present herniorrhaphy results. Diagnostic and surgical data from 25 cats with diaphragmatic hernias were analyzed retrospectively. The cats were between the ages of 2 months and 4 years, included 9 cases of males (5/9 neutered) and 16 cases of females (9/16 spayed). Acute cases were 12/25 and chronic cases were 13/25. Diaphragmatic rupture locations were defined according to the points that are determined based on a clockwise scale. Location was classified as multiple in 10 (40%), ventral in 7 (28%), right in 5 (20%), and left in 3 (12%) cases. The three most frequently herniated organs were small intestine (20, 80%), liver (16, 64%), and omentum (15, 60%). Postoperative survival rates were 83.3% for acute cases and 69.2% for chronic. Full recovery was achieved in 19 (76%) of the cats. Results suggest that the location and size of diaphragm ruptures, the organs herniated, and the presence of concurrent pathologies directly affect mortality. Mortality is higher in cases with concurrent injuries, large diaphragmatic ruptures, and excessively herniated organs.

Key words: prognosis; feline diseases; hernia; rupture; survival

Introduction

A diaphragmatic hernia occurs when organs in the abdominal cavity pass into the thoracic cavity due to an abnormal opening occurring in the diaphragm (1). Acquired diaphragmatic hernias may occur as a result of blunt trauma such as traffic accidents or falling from a high-rise (1, 2). The most common clinical finding is dyspnea (3). Other clinical findings vary depending on the herniated organs and other factors.

According to the guidance of clinical findings, the most important and simple method of

diaphragmatic hernia detection is radiography. Plain radiography shows loss of the diaphragmatic border, shadowing of the heart, increased density of the thorax, and gas deposits of the stomach or small intestine if herniated into the thoracic cavity (4). In some cases, if plain radiography does not ensure a diagnosis with a clear diaphragmatic border, contrast radiography or ultrasonography may be necessary (4, 5).

In the treatment of diaphragmatic hernias, many factors before, during, and after surgery affect the survival rate. It is a disease with a high risk of mortality because of leading significant disruptions in systems such as breathing and

digestion that directly affect the metabolism (3, 6, 7). The aim of this study, was to provide retrospective evaluations of diaphragmatic hernia in cats, according to stage of the disease, the size and localization of the diaphragm rupture, the relationship between herniated organs and other concurrent pathologies, surgical outcome, and mortality of the disease.

Material and methods

Medical records of the Hatay Mustafa Kemal University College of Veterinary Medicine (Turkey) between January 2015 and January 2020 were searched for diaphragmatic hernia cases in cats. Twenty-five cats whose owners accepted surgery and received surgical treatment were included in the study. Three cats whose owners did not accept surgery were excluded from the study. Diagnostic data such as age, gender, clinical findings, and duration of the diaphragmatic hernia were collected. Patients with a period of 14 days or less from the known trauma were considered acute, and others were considered chronic. Causes of diaphragmatic hernia were classified as motor vehicle accidents, falls from high-rise, other traumas, and unknown/trauma suspected.

For a definitive diagnosis, plain radiographs were examined including the thorax and abdomen. In cases where the diagnosis could not be confirmed by plain radiography, iohexol (30–60 mg/kg PO) (Omnipaque® GE Healthcare) was used as a contrast agent for contrast radiography. Before herniorrhaphy, diaphragm rupture lines were recorded by intraoperative determination of the clockwise direction points. According to this definition, which has not been previously given in the literature, the leftmost and most ventral tear-point of the diaphragm in the dorsal recumbency position were determined as the beginning and the rightmost and the most ventral point as the end. Accordingly, the line of tear was specified in a clockwise direction manner (Fig 1). Organs that herniated and other concurrent pathologies were determined and recorded intraoperatively. Descriptive data were reported as range, median, and mean \pm SD values.

For the perioperative effect, before surgery, a cefazolin sodium (20 mg/kg IM) was administered as an antibiotic, and meloxicam (0.3 mg/kg SC) as an analgesic. For general anesthesia, sedation was provided with xylazine hydrochloride (1–2 mg/

kg IM), and induction was provided with ketamine hydrochloride (10 mg/kg IM) (Ketasol 10 %® İnterhas). Following endotracheal intubation (No. 3–3.5), anesthesia was maintained with isoflurane (1–3 % inhalation) in 100 % O₂. In all patients, 6–8 mL/kg tidal volume (20–30 times/min, 10–15 cm H₂O) was performed. Positive end-expiratory pressure (PEEP) was 4–8 cm H₂O. A Lactated Ringer's solution (10–15 ml/kg/hr, IV) was used for perioperative fluid management.

Surgical access was provided with ventral midline celiotomy in the dorsal recumbency position. After exploration, the herniated organs were pulled out from the thoracic cavity with careful, slow, and repetitive atraumatic pulling motions. In no case was sternotomy or enlarging of the diaphragmatic rupture required to bring the herniated organs from the thoracic cavity to the abdomen. Diaphragmatic ruptures were repaired with a simple, continuous pattern of sutures made of polyglycolic acid (2/0 or 3/0) multifilament absorbable suture material. Next, the air and fluids remaining in the thorax were aspirated with a cannula and a syringe in order to provide negative pressure. Anesthesia was ended after the incision site was closed routinely. Positive pressure automatic ventilation was terminated and the patient was allowed to breathe spontaneously.

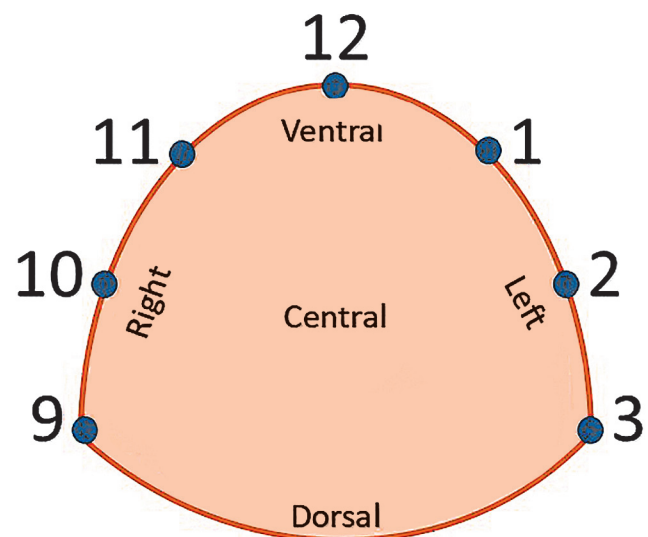


Figure 1: Diagram of the clockwise determination points in diaphragm rupture localization. The animal was assumed to be in a dorsal recumbency position in surgery

The integrity of the diaphragm line and appearance of the thorax and abdomen were checked with postoperative radiographs. For postsurgical analgesia and anti-inflammatory purposes, tolfenamic acid (2–4 mg/kg PO) was given for 5 days as NSAID. In cases with high WBC, cefazolin (20 mg/kg IM) was administered for 7 days postoperatively. For supportive treatment, a supplement containing iron along with cobalt, vitamin B12 and vitamin B3 (1–2 drops / kg PO, Fercobsang, Novakim®, Turkey) was given for 5 days in cases that resulted in low hematocrit and hemoglobin values of complete blood count analysis. Clinical improvements, complications, and survival were recorded for at least 10 days postoperatively.

Results

All of the patients diagnosed with diaphragmatic hernia were domestic shorthair cats. The age range was 2 months to 4 years old (median 7 months). The gender distribution was 16/25 (64 %) females (9/16 spayed) and 9/25 (36 %) males (5/9 neutered). The time between trauma and diagnosis ranged from 3 hours to 5 months (median 7 days, mean 20.7 days, SD±34.4). The stage of the disease was acute in 12 cases (48 %) and chronic in 13 cases (52 %). It was determined that 11 (44 %) of the cases were caused by trauma not seen by the owners, 9 (36 %) by motor vehicle accident, 3 (12 %) by other physical trauma, and 2 (8 %) by falls from a high-rise (Table 1). Typical findings such as dyspnea, tachypnea, open-mouth breathing, exercise intolerance, abdominal breathing, anorexia, and vomiting were seen in clinical examinations.

Table 1: Demographic and diagnostic information of cases

Case No	Sex	Age (Months)	Time ^a (Days)	Cause	Category
1	F	9	150 ^b	Unknown /suspected trauma	Chronic
2	F	2	2	Other trauma	Acute
3	F	7	60 ^b	Motor vehicle accident	Chronic
4	F	4	14 ^b	Unknown /suspected trauma	Chronic
5	F	6	30 ^b	Unknown /suspected trauma	Chronic
6	F	2	1	Motor vehicle accident	Acute
7	M	12	0	High-rise fall	Acute
8	F	3	9	Unknown /suspected trauma	Chronic
9	M	10	2	Unknown /suspected trauma	Acute
10	M	10	14 ^b	Motor vehicle accident	Chronic
11	F	9	60 ^b	Motor vehicle accident	Chronic
12	F	3	14 ^b	Unknown /suspected trauma	Chronic
13	F	3	14 ^b	Unknown /suspected trauma	Chronic
14	M	48	1	Other trauma	Acute
15	M	24	14 ^b	Unknown /suspected trauma	Chronic
16	M	18	90	Motor vehicle accident	Chronic
17	M	12	1	High-rise fall	Acute
18	F	12	14 ^b	Motor vehicle accident	Chronic
19	F	2	2	Motor vehicle accident	Acute
20	M	7	1	Unknown /suspected trauma	Acute
21	F	12	5	Other trauma	Chronic
22	F	4	1	Unknown /suspected trauma	Acute
23	F	6	5	Motor vehicle accident	Acute
24	F	6	1	Unknown /suspected trauma	Acute
25	M	4	7	Motor vehicle accident	Acute

F: Female, M: Male, a: From trauma to admission; b: It is known to be more than

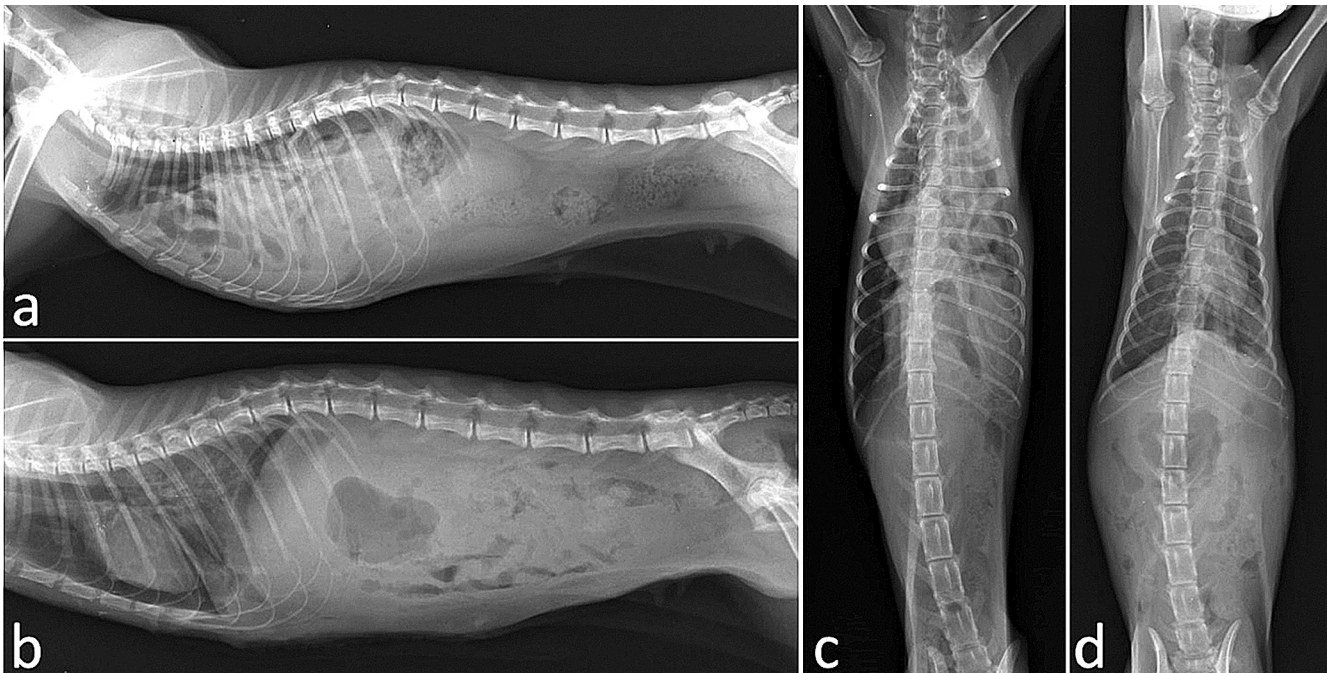

Figure 2: Plain radiographic images of a cat with a diaphragmatic hernia. Preoperative (a, c) and postoperative (b, d) images show the abdominal organs filled in the thorax before surgery, and in their normal position postoperatively

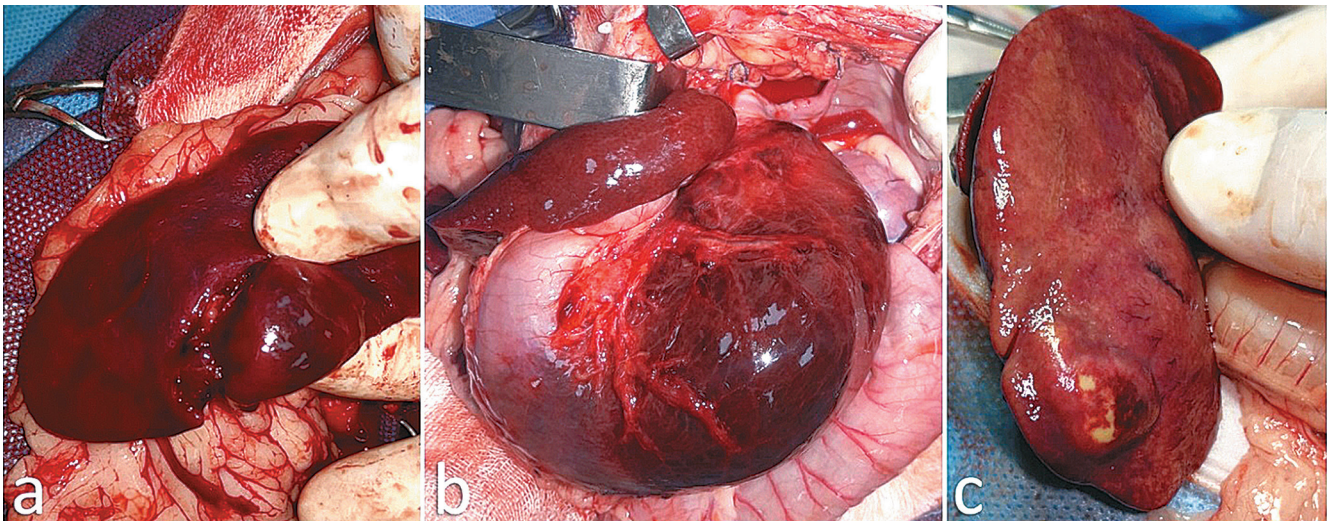


Figure 3: Samples of intraoperative images of organ pathologies associated with diaphragmatic herniated cats: spleen rupture (a); gastric torsion (b); and hepatic abscess (c)

In radiographic examinations, a definitive diagnosis was achieved in 21 cases by plain radiography. In 4 cases where definitive diagnosis could not be determined by plain radiography, the diagnosis was confirmed with contrast (gastrointestinal) radiography. Radiographic examinations revealed that the diaphragm line disappeared, and the intestines, liver, stomach, and other abdominal organs were in the thoracic cavity displaced (Fig 2). Other concurrent disorders or damages were determined by clinical, phys-

ical, and radiographic examinations, or during surgery.

In addition to the diaphragmatic hernia, 7 cases of orthopedic damage were detected in 6 cats, and 12 cases soft-tissue damage or pathology in 10 cats (some examples can be seen in Fig 3 and all of concurrent damages/disorders are presented in Table 2). The most common starting points of tearing in the diaphragm were noted towards 9 o'clock in 14 (56 %) cases, 10 o'clock in 5 (20 %) cases, and 12 o'clock in 3 (12 %) cases.

Table 2: Herniated organs and numbers, diaphragm rupture lines (clockwise), concurrent damages, and surgical outcomes of cases

Case No	Organs herniated		Diaphragm rupture line (clockwise)				Concurrent injuries or pathologies	Surgical Outcome
	Organs	Number	Region	Start	End	Width ^a		
1	L, GB, SI, LI	4	Multiple	9	2	5		Survived
2	O, SI	2	Left	1	3	2	Enlarged GB, Femoral F	Survived
3	L, SI, LI	3	Left	12	3	3		Survived
4	O, SI	2	Right	9	12	3		Died (13th day)
5	RK, L (one lobe), O, SI	4	Right	9	11	2	Spleen displaced (to right)	Survived
6	St, O, SI	3	Ventral	10	12	2	Neck (soft tissue) injury	Survived
7	O, Sp	2	Rright	9	12	3	Spleen rupture, Femoral F	Survived
8	St, O, SI	3	Ventral	11	2	3	Hepatic abscess, Femoral F	Survived
9	St, O, SI, LI, Sp	5	Right	9	12	3	Gastric torsion	Survived
10	L, GB, SI, LI	4	Left	12	3	3	Megaesophagus	Died (8th day)
11	L, GB, St, P, Sp, SI, LI	7	Multiple	9	1	4	Splenomegaly	Survived
12	L, St	2	Multiple	9	3	6		Died (on 10th day)
13	St, SI, LI	3	Ventral	10	12	2		Survived
14	L, St, O, SI	4	Ventral	10	1	3	Pelvic F	Survived
15	L, O, SI	3	Multiple	9	1	4		Survived
16	L, St, O, SI, Sp	5	Multiple	11	3	4	Splenomegaly, Enlarged GB	Survived
17	St, O	2	Ventral	12	1	1		Died (in 24 hours)
18	L, GB, O, SI	4	Multiple	9	1	4	SIL, Pelvic MF	Died (in 24 hours)
19	L, St, O, SI	4	Multiple	9	1	4	Abdominal hernia	Survived
20	L, St, Sp	3	Multiple	9	1	4	Spleen rupture	Died (in 3 h)
21	L, GB, SI	3	Multiple	9	2	5		Survived
22	St, O	2	Ventral	10	1	3		Survived
23	L, SI, LI	3	Right	9	12	3		Survived
24	L, O, Sp, SI	4	Ventral	10	1	3		Survived
25	L, SI	2	Multiple	9	3	6		Survived

a: Units were given in hours, L: Liver, GB: Gall bladder, SI: Small intestine, LI: Large intestine, O: Omentum, RK: Right kidney, St: Stomach, Sp: Spleen, P: Pancreas, SIL: Sacroiliac luxation, F: Fracture, MF: Multiple fractures

Table 3: Distribution of herniated organs according to diaphragmatic rupture localization.

Organs	Right	Left	Ventral	Multiple	Total
Small intestines	4/20 (20 %)	3/20 (15 %)	5/20 (25 %)	8/20 (40 %)	20 (80 %)
Liver	2/16 (12,5 %)	2/16 (12,5 %)	2/16 (12,5 %)	10/16 (62,5 %)	16 (64 %)
Omentum	4/15 (26,7 %)	1/15 (6,7 %)	6/15 (40 %)	4/15 (26,7 %)	15 (60 %)
Stomach	1/12 (8,3 %)	-	6/12 (50 %)	5/12 (41,7 %)	12 (48 %)
Large intestines	2/7 (28,6 %)	2/7 (28,6 %)	1/7 (14,3 %)	2/7 (28,6 %)	7 (28 %)
Spleen	2/6 (33,3 %)	-	1/6 (16,7 %)	3/6 (50 %)	6 (24 %)
Gall bladder	-	1/5 (20 %)	-	4/5 (80 %)	5 (20 %)
Pancreas	-	-	1/1 (100 %)	-	1 (4 %)
Kidney (Right)	1/1 (100 %)	-	-	-	1 (4 %)

Table 4: Complete blood count and serum biochemistry results of the cases (N: Normal)

Parameter/ Case No	Reference Ranges	Case 1	Case 2	Case 3	Case 4	Case 5	Case 6	Case 7	Case 8	Case 9
WBC	5,5-19,5	20,1	19,6	28,5	25,4	22,8	21,7	30,4	27,9	N
Lymphocyte	1-7	7,8	N	12,7	8,9	8,9	10,3	11,8	13,9	N
Monocyte	0,07-1,9	2,4	N	3	2,9	2,5	N	N	N	N
Eosinophils	0-4	N	N	N	5,4	N	N	N	7,2	N
Granulocytes	35-85	N	87,8	N	87,6	N	N	N	N	N
RDW	14-18	N	N	N	N	N	19,9	N	N	N
HGB	9.3-15,3	N	N	N	7,9	8,5	N	7,7	N	N
HCT	28-49	N	N	N	25,9	25,3	N	24,2	N	N
PLT	100-514	N	N	N	85	N	N	N	N	75
ALT	10-101	136	N	245	N	N	N	N	N	458
AST	7-80	87,6	N	95,7	N	N	N	N	N	91,3
GLU	60-150	N	N	N	155	N	N	N	N	172
CRE	0,9-2,20	N	N	N	N	N	N	N	0,8	N
Fe	68-215	N	N	N	54,9	N	N	N	N	N
ALB	2,1-4,6	N	N	N	2	N	N	N	N	N
Ca	8,8-11,7	N	N	N	N	N	N	N	N	N

Parameter/ Case No	Reference Ranges	Case 10	Case 11	Case 12	Case 13	Case 14	Case 15	Case 16	Case 17
WBC	5,5-19,5	N	20,6	35,8	N	32	N	21,9	35,7
Lymphocyte	1-7	N	9,8	8,9	N	N	8,3	9,3	7,3
Monocyte	0,07-1,9	N	3,1	3,6	N	N	2,5	3,3	2,7
Eosinophils	0-4	N	N	N	10,3	N	N	N	N
Granulocytes	35-85	N	N	95,7	N	N	N	N	N
RDW	14-18	N	N	19,5	N	N	N	N	19,3
HGB	9.3-15,3	N	7,6	7,3	N	8	N	7,6	7,3
HCT	28-49	N	23,9	22,9	N	27,5	N	22,7	22
PLT	100-514	N	N	87,6	N	N	N	N	79,6
ALT	10-101	N	N	129,3	135	322	141	N	155,7
AST	7-80	N	N	98,3	N	209	90,4	N	89,5
GLU	60-150	N	N	N	410	N	N	N	162,4
CRE	0,9-2,20	N	N	0,7	0,9	0,3	N	N	N
Fe	68-215	N	N	53,9	N	61,7	N	N	N
ALB	2,1-4,6	N	N	1,9	N	1,6	N	N	N
Ca	8,8-11,7	N	N	N	N	7,4	7,4	N	N

Parameter/ Case No	Reference Ranges	Case 18	Case 19	Case 20	Case 21	Case 22	Case 23	Case 24	Case 25
WBC	5,5-19,5	N	22,9	N	25,3	N	19,9	20,1	23,6
Lymphocyte	1-7	N	12,3	N	8,5	7,6	7,4	7,9	8,3
Monocyte	0,07-1,9	2,1	N	N	2,9	N	N	N	N
Eosinophils	0-4	11,1	N	4,7	N	N	N	N	N
Granulocytes	35-85	N	86,7	N	89,5	N	N	N	N
RDW	14-18	22,4	N	N	19,3	N	N	N	N
HGB	9.3-15,3	6,1	8,3	6,1	N	9,1	N	N	N
HCT	28-49	22,9	25,4	21,7	N	25,9	N	N	N
PLT	100-514	72	N	N	85	N	96,2	94,7	95,4
ALT	10-101	N	N	120,9	N	126,3	105,7	N	N
AST	7-80	N	N	89,6	N	N	N	N	N
GLU	60-150	N	N	N	155,6	N	156,7	N	N
CRE	0,9-2,20	0,9	N	0,8	N	N	N	N	N
Fe	68-215	59,3	N	54,9	N	N	N	N	N
ALB	2,1-4,6	N	N	N	N	N	N	N	N
Ca	8,8-11,7	N	N	N	N	8,5	N	N	N

The most common end points were towards 1 o'clock in 9 (36 %) cases, 12 o'clock in 6 (24 %) cases, and 3 o'clock in 6 (24 %) cases (Table 2). The extent of the diaphragm ruptures was in the range of 1–6 units according to the starting and ending points in a clockwise direction (median 3, mean 3.4, SD±1.2). The distribution of the herniated organs according to diaphragmatic rupture localization is presented in Table 3.

Surgical repair of diaphragmatic hernias resolved clinical signs of tachypnea, dyspnea, exercise intolerance, vomiting, and anorexia in 17/25 (68 %) cats. Respiratory or gastrointestinal tract signs were detected after surgery in 2/25 cats (8 %). Despite all the interventions (intravenous fluid support, postoperative care that supports oxygen and body temperature in the intensive care unit, and cardiopulmonary resuscitation treatment), death occurred due to postanesthetic cardiac arrest in the first 24 hours in 3/25 cases. In addition, 3/25 cats died on the eighth, tenth, and thirteenth days owing to the owners' postoperative care neglect leading to septicemia. Therefore, the perioperative and postoperative mortality rates were both determined as 12 %. Concurrent disruptions such as megaesophagus, spleen rupture, and multiple fractures were determined in these cases. From a complete blood count, WBC and lymphocyte was high in 18 cases, monocyte and eosinophils in 8 cases, and granulocytes and RDW in 5 cases. Low values of HGB and HCT were found in 12 cases, and of PLT in 9 cases. Biochemistry values were high in ALT in 11, AST in 8, and glucose in 6 of the patients. Low values of creatinine were found in 6 cases, of Fe in 5 cases, and of ALB and Ca in 3 cases (The abnormal complete blood count and serum biochemistry results are presented in Table 4). Complete recovery was achieved in 19 (76 %) of the 25 cats treated surgically. Survival rates in acute and chronic cases were 83.3 % and 69.2 %, respectively.

Discussion

It has been reported in previous scientific studies that 77–85 % of diaphragmatic hernias in cats are due to trauma (8, 9, 10). In our study, all cases (100 %) were traumatic diaphragmatic hernias, and none were congenital. Various studies have reported that diaphragmatic hernia is more common in male cats, but in our study most

(64 %) of the cases were female (9/16 of females were spayed and 5/9 of males were neutered; 21/25 were indoor cats and 4/21 were outdoor) (4, 6, 7, 11, 12, 13). Although the gender of the patients is stated in the studies, sterilization information and life circumstances (indoor/outdoor) seems to be lacking. It has been stated in other studies that contrast gastrointestinal radiographs, celiorrhaphy, and ultrasonography are also useful (5, 13, 14, 15). Contrast gastrointestinal radiographs are advantageous in that the stomach and intestines are clearly visible in the thorax. However, they may not be sufficient in a situation such as partial obstruction of the gastrointestinal system which prevents the passage of the contrast agent. Positive contrast celiorrhaphy has the disadvantage of giving false negative results if the defect in the diaphragm is occluded with abdominal organs (5, 15). In the present study, plain and contrast gastrointestinal radiographs were found to be adequate. Clinical and radiographic signs of patients in the present study were similar to those in other reports (1, 6). Recently, researchers have considered diaphragmatic hernia cases that last over 2 weeks as chronic (3, 6).

Many risk factors are known as causes of postoperative surgical site infection under the headings of patient, environmental, and therapeutic factors to be (16, 17). Perioperative use of antibiotics is known to reduce the risk of infection (16, 18). Postoperative antimicrobial use is known to be unnecessary for clean surgeries, but is required when patients show signs of infection in the presence of major risks of breakage in sterility of surgery or other factors (16). However, it has been controversial in surgeries classified as clean-contaminated (17). Eugster et al. (16) reported that, although 84.2 % of 836 cases in their study were surgeries performed under clean or clean-contaminated conditions, postoperative antibiotics were used in 77.5 % of cases. In some studies, it has been reported to be unnecessary except for contaminated and dirty wounds (16). Another study suggests antimicrobial therapy in the surgical patient for decreased short-term morbidity and prevention of devastating infection risk (19). In the present study, perioperative and postoperative antibiotics were used, taking into account WBC in complete blood count analysis. The preference for cefazolin was due to its broad spectrum and the local supply facilities for the patients' owners.

Some authors may resort to additional techniques such as median sternotomy, lateral thoracotomy, or widening of the diaphragmatic rupture during the retracting of herniated organs from the thorax to the abdomen (6, 11, 13, 20, 21). In this study, as in recent studies, the ventral median celiotomy had provided adequate access for the repair of the diaphragmatic rupture (21). However, these additional methods should not be avoided if the organs are likely to be damaged during replacement. In standard herniorrhaphy repairs it is not necessary to place a thoracostomy tube. However, it is necessary if the patient has pneumothorax or respiratory distress, or if there are any extra-routine conditions such as sternotomy during herniorrhaphy, damage to the pericardium, or chylothorax in the pleural space. Thoracostomy tube application can be performed for drainage or to give intrapleural analgesics (22). Nevertheless, it is not recommended if not necessary due to its complication risks, increased hospitalization time, and morbidity (23, 24). In our study, no additional technique was performed except for ventral midline celiotomy. Therefore, there was considered to be no need to insert a thoracostomy tube.

The use of polydioxanone, glycomer, polypropylene, polygluconate, polyglycolic acid, and polyglactin 910 has been reported as suture material in diaphragmatic hernias (6, 25, 26, 27). Some authors find the use of polydioxanone and glycomer appropriate and avoid the use of others (26). In some studies, the use of polyglycolic acid and polyglactin 910 suture materials is reported as a suitable choice (1, 25, 27). In this study, the absorption time was considered sufficient for healing. Polyglycolic acid, an absorbable material, was preferred in suture application because of the advantages of being pliable, soft, and easy to handle (28). There was no complication in the results related to breakdown of the integrity of the tear repair.

Diaphragmatic hernia is a disease with a high risk of mortality in cats. Various factors before, during, and after surgery affect the survival rate (3, 6, 7). It has been reported that mortality is higher when there are complications such as pneumothorax, lobe torsion, necrosis of the liver or lung, and strangulation of the intestines during the chronicization process (6, 13). Besalti et al. (6) reported that mortality rates in diaphragmatic hernias in cats are related to the

location of the diaphragm rupture as well as the stage of the disease, and mortality is higher in ruptures in the center of the diaphragm. Studies evaluating localization of the diaphragm rupture in diaphragmatic hernias of cats are limited (6, 29). Besalti et al. (6) reported that their study was the first in which localization and mortality were evaluated together. They described the localization of diaphragmatic ruptures as right, left, central, ventral, dorsal, and multiple. In our study, we determined the localization and quantity of ruptures according to the clockwise direction for the first time, which we considered a precise method of determining of the rupture line. It has been reported that in diaphragmatic hernias, the herniation is mostly seen on the right side (4, 6, 12, 30). In our study, herniation was largely (40 %) on both sides. One study has suggested that if the rupture is on the right side, the liver acts as a barrier to prevent herniation (11), however, Besalti et al. (6) stated that this hypothesis is not valid. Our study also weakens the validity of this hypothesis by showing that the liver and other organs accompany diaphragmatic hernias frequently.

In diaphragmatic hernias of cats and dogs, the most herniated organs have been identified as the liver, small intestines, stomach, omentum, spleen, pancreas, and large intestines, respectively (4, 6, 7, 30). In this study, the most herniated organs were identified as the small intestines on the left and right sides, the stomach and omentum on the ventral side, and the liver on multiple-sided ruptures.

Schmiedt et al. (7) suggested in their study that mortality does not have a significant relationship with herniated organs. Besalti et al. (6) noted that among 21 chronic cases, the commonality point of 5 cases that died was herniation of the liver. Nevertheless, in many of the healed cats, the liver is among the herniated organs and could not be directly associated with mortality. However, they stated that the number of herniated organs has a significant effect on mortality (6). In our study, due to the fact that there were 2 or more organs herniated in all cases, a direct correlation between the number of herniated organs and mortality could not be proven. Although there was no statistical evidence in this study, it is suggested based on the authors' observations that impairment of the volume or function of the organ may increase mortality and affect the

surgical outcome. Another study stated that, if the intestines or stomach herniated, undesirable conditions such as motility disorders and vomiting occurred before or after surgery. In addition, many problems such as megaesophagus, heart disease, pulmonary disease, or liver disease can occur in the pre- or postoperative periods (22). These facts supports the hypothesis that complications caused by diaphragmatic herniated organs affect mortality.

In previous studies, it has been stated that prolonged surgical procedures and anesthesia, perioperative oxygen needs, and concurrent injuries are significantly associated with mortality. Mortality rates have been reported to be 4.3 times as high in cases with concurrent soft-tissue injury, and 7.3 times as high if there are soft tissue and orthopedic injuries occur together (3,7). In our study, there were concurrent pathologies in 3 (50 %) of 6 cases in which death occurred. However, 9 (47.37 %) of the 19 recovered cases also had concurrent damage or pathologies. Similarly, in other studies, concurrent injuries did not significantly change the mortality (6, 31). Therefore, the main factor in the increase in mortality is the extent to which concurrent injuries or pathologies. In previous studies, chronic diaphragmatic hernia of cats have been reported with worse surgical outcomes (8). This is because diaphragmatic hernia cases with a history of more than 1 year were considered chronic. In recent studies, diaphragmatic hernia cases have been considered as chronic if patients have had them for 15 days or more (13, 32), thus making the results difficult to compare with the former studies.

Perioperative mortality rates in different studies range from 8–18 % in different studies (7, 31). In our study, perioperative mortality rate were 2/25 of cases as similar to previous studies. The reported postoperative survival rates are between 54 % and 90 % (3, 6, 7, 8, 9, 29, 33, 34). Mortality rates in cats with acute and chronic traumatic diaphragmatic hernia have been reported as 16.1–20 % and 11.8–19 %, respectively (6, 7). In our study, mortality rates in acute and chronic cases were 2/12 and 4/13, respectively. The overall survival rate was 19/25 (10/12 acute, 9/13 chronic). The majority of cases were with a large ruptured diaphragm, which is an important factor that reduces survival rates, but these results are close to those in the aforementioned studies.

In some studies, it has been reported that the risk of mortality increases significantly in patients with diaphragmatic hernia operated on within 24 hours following trauma (8, 33). For this reason, it is recommended to postpone surgery (8). However, because of the development of surgical equipments and care conditions in the over the years, recent studies have suggested that there is no relation between the timing of the surgery and survival (3, 32). Based on this, it has been suggested that preoperative stabilization and perioperative support would be sufficient and the surgery should not be postponed even for 24 hours (3). In our study, only one patient was operated on less than 24 hours after trauma. The surgery was performed on the same day as the proper preoperative stabilization. In spite its concurrent orthopedic and soft-tissue injuries, this patient survived.

In cats with acquired diaphragmatic hernia, the location, size, type, and concurrent injuries and pathologies directly affect the perioperative mortality rate. The risk of mortality is higher in cats with a diaphragmatic hernia in the presence of different concurrent pathologies, orthopedic injuries, or soft-tissue injuries. Further studies are needed to investigate the surgical outcomes and prognostic factors with detailed measurements in diaphragmatic hernias of cats and dogs.

Acknowledgments

The authors would like to thank Dr. Halil Alakuş and Dr. Ömer Kirgiz for their help in the clinical work.

The authors declare that there are no conflicts of interest.

References

1. Ozer K, Guzel O, Devecioglu Y, Aksoy O. Diaphragmatic hernia in cats: 44 cases. *Med Wet* 2007; 63: 1564–7.
2. Yaygingül R, Bozkan Z, Şen BZ, Kurt BK, Belge A. Traumatic diaphragmatic hernia in cats: a retrospective study of 15 cases (2016–2017). *Kocatepe Vet J* 2019; 12(2): 205–12. doi: 10.30607/kvj.493594
3. Legallet C, Mankin KT, Selmic LE. Prognostic indicators for perioperative survival after diaphragmatic herniorrhaphy in cats and dogs: 96 cases (2001–2013). *BMC Vet Res* 2016; 13(1): e16. doi: 10.1186/s12917-016-0926-y

4. Hyun C. Radiographic diagnosis of diaphragmatic hernia: review of 60 cases in dogs and cats. *J Vet Sci* 2004; 5: 157–62.
5. Bradley K. Practical contrast radiography 2: Gastrointestinal studies. In *Pract* 2005; 27: 412–7.
6. Besalti O, Pekcan Z, Caliskan M, Aykut GZ. A retrospective study on traumatic diaphragmatic hernias in cats. *Ankara Univ Vet Fak Derg* 2011; 58: 175–9.
7. Schmiedt CW, Tobias KM, Stevenson MM. Traumatic diaphragmatic hernia in cats: 34 cases (1991–2001). *J Am Vet Med Assoc* 2003; 222: 1237–40. doi: 10.2460/javma.2003.222.1237
8. Boudrieau JR, Muir MW. Pathophysiology of traumatic diaphragmatic hernia in dogs. *Compend Contin Educ Pract Vet* 1987; 9: 379–85.
9. Wilson GPT, Hayes HMJ. Diaphragmatic hernia in the dog and cat: a 25-year overview. *Semin Vet Med Surg* 1986; 1: 318–26.
10. Worth AJ, Machon GR. Traumatic diaphragmatic herniation: pathophysiology and management. *Compend Contin Educ Pract Vet* 2005; 27: 178–91.
11. Stokhof AA. Diagnosis and treatment of acquired diaphragmatic hernia by thoracotomy in 49 dogs and 72 cats. *Vet Q* 1986; 8: 177–83.
12. Bellenger JR, Hunt GB, Goldsmid, ES, Pearson BMR. Outcomes of thoracic surgery in dogs and cats. *Aust Vet J* 1996; 74: 25–30. doi: 10.1111/j.1751-0813.1996.tb13729.x
13. Minihan AC, Berg J, Evans KL. Chronic diaphragmatic hernia in 34 dogs and 16 cats. *J Am Anim Hosp Assoc* 2004; 40: 51–3. doi: 10.5326/0400051
14. White DJ, Tisdall LP, Norris JM, Malik R. Diaphragmatic hernia in a cat mimicking a pulmonary mass. *J Feline Med Surg* 2003; 5: 197–201. doi: 10.1016/S1098-612X(02)00069-4
15. Stickle LR. Positive-contrast celio-graphy (peritoneography) for the diagnosis of diaphragmatic hernia in dogs and cats. *J Am Vet Med Assoc* 1984; 185: 295–8.
16. Eugster S, Schawalder P, Gaschen F, Borerlin P. A prospective study of postoperative surgical site infections in dogs and cats. *Vet Surg* 2004; 33: 542–50.
17. Nelson LL. Surgical site infections in small animal surgery. *Vet Clin North Am Small Anim Pract* 2011; 41: 1041–56.
18. Nicholson M, Beal M, Shofer F, Brown DC. Epidemiologic evaluation of postoperative wound infection in clean-contaminated wounds: a retrospective study of 239 dogs and cats. *Vet Surg* 2002; 31: 577–81.
19. Findji L. Antibiotics in surgical patients. *Clinician's Brief* 2014; (May): 19–22. <https://www.cliniciansbrief.com/article/antibiotics-surgical-patients> (01. 11. 2020)
20. Walker GR, Hall LW. Rupture of the diaphragm: Report of 32 cases in dogs and cats. *Vet Rec* 1965; 77: 830–7.
21. Hunt BG, Johnson AK. Diaphragmatic, pericardial, and hiatal hernia. In: Slatter DH, ed. *Text-book of small animal surgery*. Philadelphia : Elsevier, 2002: 471–87.
22. Burns CG, Bergh MS, McLoughlin AM. Surgical and nonsurgical treatment of peritoneopericardial diaphragmatic hernia in dogs and cats: 58 cases (1999–2008). *J Am Vet Med Assoc* 2013; 242: 643–50. doi: 10.2460/javma.242.5.643
23. Chan L, Reilly KM, Henderson C, Khan F, Salluzzo FR. Complication rates of tube thoracostomy. *Am J Emerg Med* 1997; 15: 368–70. doi: 10.1016/S0735-6757(97)90127-3
24. McPhail CM. Medical and surgical treatment of pyothorax. *Vet Clin North Am Small Anim Pract* 2007; 37: 975–988. doi: 10.1016/j.cvsm.2007.05.012
25. Lee JH, Yang WJ, Kang EH, et al. Diaphragmatic hernia in dogs: 4 cases. *J Vet Clin* 2009; 26: 62–8.
26. Pratschke K. Management of hernias and ruptures in small animals. In *Pract* 2002; 24: 570–81.
27. McClaran JK. Diaphragmatic and peritoneopericardial diaphragmatic hernias. Monnet E, ed. In: *Small animal soft tissue surgery*. Philadelphia : Saunders, 2012: 278–85.
28. Kladakis S. Choosing sutures in small animal surgery. *J Dairy Vet Anim Res* 2014; 1(3): 68–71. doi: 10.15406/jdvar.2014.01.00015
29. Wilson GP, Newton CD, Burt JK. A review of 116 diaphragmatic hernias in dogs and cats. *J Am Vet Med Assoc* 1971; 159: 1142–5.
30. Marlof A, Kraft S, Lowry J, Pelsue D, Veir J. Radiographic diagnosis right kidney herniation in a cat. *Vet Radiol Ultrasound* 2002; 43: 237–40. doi: 10.1111/j.1740-8261.2002.tb00996.x
31. Kraje BJ, Kraje AC, Rohrbach BW, Anderson AK, Steven ML, Macintire DK. Intrathoracic and concurrent orthopedic injury associated with traumatic rib fracture in cats: 75 cases

(1980–1998). *J Am Vet Med Assoc* 2000; 216: 51–4. doi: 10.2460/javma.2000.216.51

32. Gibson GTW, Brisson AB, Sears W. Perioperative survival rates after surgery for diaphragmatic hernia in dogs and cats: 92 cases (1990–2002). *J Am Vet Med Assoc* 2005; 227: 105–9. doi: 10.2460/javma.2005.227.105

33. Sullivan M, Reid J. Management of 60 cases of diaphragmatic rupture. *J Small Anim Pract* 1990; 31: 425–30. doi: 10.1111/j.1748-5827.1990.tb00503.x

34. Brody RS, Sauer MR. Clinico-pathologic conference. *J Am Vet Med Assoc* 1964; 145: 1213–22.

HERNIORAFIJA IN KIRURŠKI IZIDI DIAFRAGMALNE KILE PRI MAČKAH

M. Z. Y. Deveci, Z. Yurtal, C. T. İşler, S. B. Emiroğlu, İ. Alakuş, M. E. Altuğ

Izveček: Namen te študije je bil ovrednotiti kirurški izid in smrtnost diafragmalne kile pri mačkah ter predstaviti rezultate herniorafije. Retrospektivno smo analizirali diagnostične in kirurške podatke pri 25 mačkah z diafragmalno kilo. Mačke so bile stare od 2 mesecev do 4 let, med njimi je bilo 9 samcev (5/9 kastriranih) in 16 samic (9/16 steriliziranih). Akutnih primerov je bilo 12/25 in kroničnih 13/25. Mesta pretrganja diafragme so bila opredeljena glede na točke, določene na podlagi lestvice v smeri urinega kazalca. Pretrganje je bilo določeno kot večmestno v 10 (40%) primerih, ventralno v 7 (28%), desno v 5 (20%) in levo v 3 (12%) primerih. Trije najpogosteje vrinjeni organi so bili tanko črevo (20,80%), jetra (16,64%) in omentum (15,60%). Preživetje po operaciji je bilo pri akutnih primerih 83,3%, pri kroničnih pa 69,2%. Popolno okrevanje je bilo doseženo pri 19 (76%) mačkah. Rezultati kažejo, da na umrljivost neposredno vplivajo mesto in velikost raztrganine diafragme, vrinjeni organi in prisotnost sočasnih patologij. Smrtnost je večja pri sočasnih poškodbah, velikih raztrganinah diafragme in prekomernem vrinjenju organov.

Ključne besede: prognoza; boleznima mačk; kila; raztrganina; preživetje